

CS 8100 3D and CS Solutions

CBCT and CAD/CAM Allow for One-Day Restoration of Tooth #9

Robert Pauley, Jr., DMD

Case Overview

Our office received a frantic phone call from the mother of one of our twelve-year-old patients, who stated that her daughter fell while in P.E. class and broke a front tooth. We advised her to bring her daughter to the office as soon as possible. Immediately after her arrival a periapical radiograph of tooth #9 and extraoral photographs were obtained (Fig. 1). Upon clinical examination and review of the digital radiograph, I saw tooth #9 was horizontally fractured at the middle third. There was no pulp exposure evident, but the tooth did have a pinkish tint on the lingual. No mobility was noted and no periapical changes or root fractures were obvious at this time. The new American Association of Endodontists guidelines recommend taking one occlusal and two periapical radiographs with different lateral angulations for all dental injuries, including crown fractures. If cone beam-computed tomography is available, it should be considered to reveal the extension and direction of the fracture.¹ Dr. Edward Mills in his presentation on Site Development and Implant Protocol Based on Etiology of Tooth Loss refers to a similar traumatic injury in which CT images revealed not only a root fracture within the bone but a fracture of the lingual plate.²

A limited field 3D scan 5cm x 5cm at 300 voxels was taken with the CS 8100 3D to rule out buccal or palatal plate fractures (Fig. 2). None were evident on the scan. While her parents were upset that she had been injured, the ability to view a 3D image reassured them that the damage appeared to be limited to the tooth's coronal structure.



Robert Pauley, Jr., DMD

Dr. Pauley has been practicing dentistry in the Atlanta area since graduating from the University of Kentucky College of Dentistry in 1988. Currently enrolled in the Advanced Dental Implant Studies, Dr. Pauley is an Associate Fellow of the American Academy of Implant Dentistry and a Fellow of the International Congress of Oral Implantologists.

Clinical Case Study

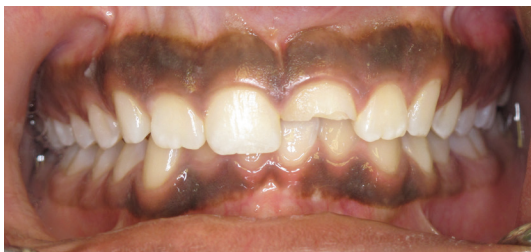

Figure 1

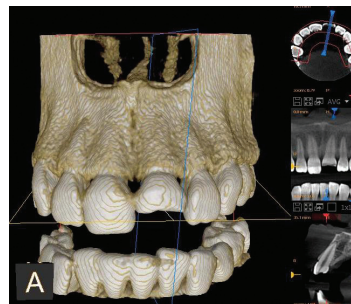


Figure 2



Clinical Case Study



Treatment Plan:

The patient's treatment options were: 1) do nothing; 2) restore with a composite restoration, realizing that this would have a questionable long-term prognosis due to size of fracture; 3) restore with a CAD/CAM milled crown. The patient and her parents were advised that cases where teeth have been injured traumatically such as in this case, one might experience a post traumatic irreversible pulpitis at a period of time beyond the initial trauma. In some cases, this condition may be treated by endodontic treatment and crown restorations but in other cases root resorption may take place precipitating the loss of the teeth. These teeth will be monitored every 6 months over several years with periapical radiographs. Every appropriate effort to maintain the tooth in place and avoid the need of an implant until the patient reaches maturity. Dental implants in adolescent patients may affect vertical growth and development of the alveolar ridge because the osseointegrated implant acts as an ankylosed tooth. At a focus conference on Advanced Dental Implant Studies, Dr. Mills summarized that jaw growth in a young adolescent patient may compromise the outcome of the oral rehabilitation using an implant supported prosthesis even if implants successfully integrated. After presentation of the treatment plan and discussion of risks, benefits, options, and alternatives; the parents and patient elected to restore tooth #9 with a CAD/CAM crown. The parents understand this crown will likely need to be replaced once she reaches adulthood for the best cosmetic appearance, as her teeth and face will change with further growth and development.

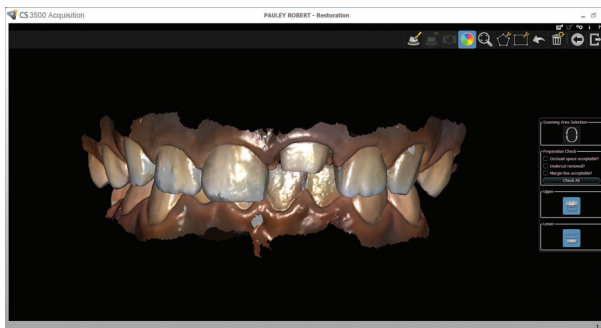


Figure 3

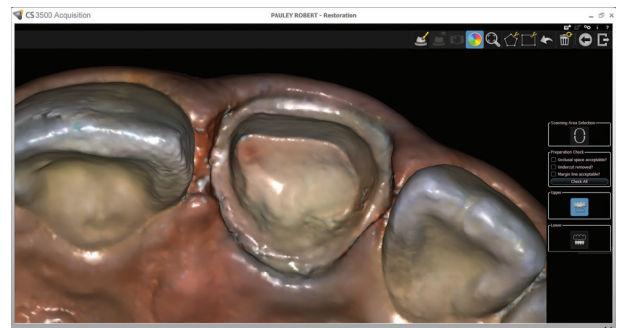


Figure 4

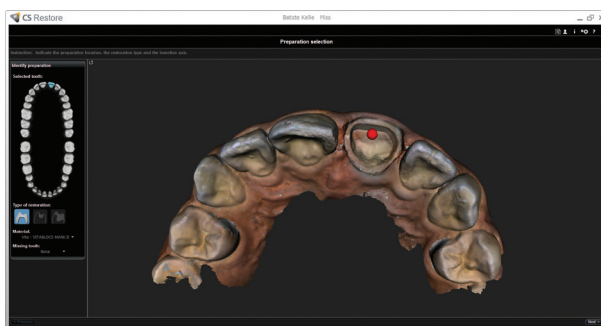


Figure 5

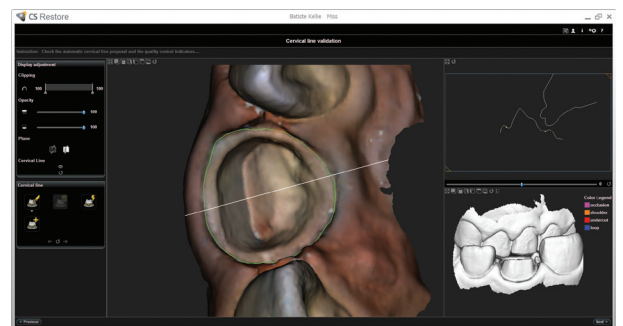


Figure 6

Clinical Case Study

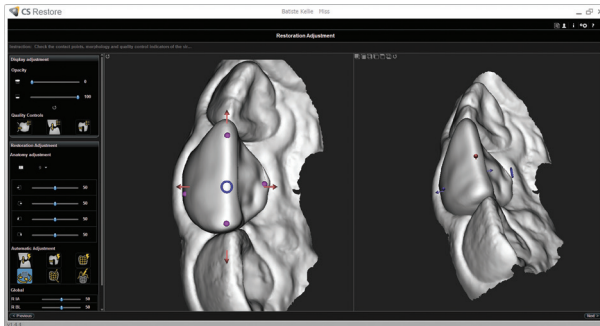


Figure 7

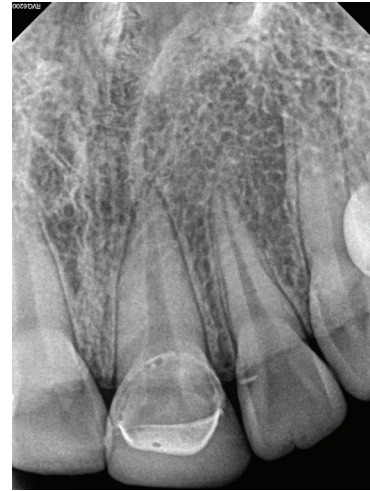

Figure 8

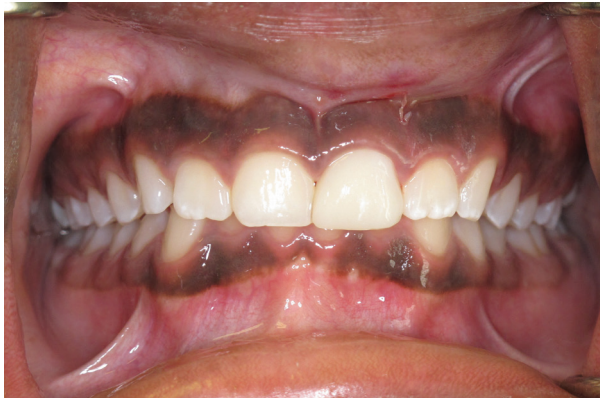

Figure 9

Tooth # 9 was anesthetized and prepared for a ceramic crown. I utilized the CS 3500 intraoral scanner to scan the prepared maxillary anterior quadrant and the opposing mandibular anterior quadrant as well as obtain a bite registration (Figs 3, 4). CS Restore software was then utilized to design the anterior crown (Figs. 5-7). The CS 3000 milled the crown from an Ivoclar Vivadent e.max shade A1 size 12 ceramic block. We tried in the crown and took a digital PA radiograph to verify the margination, and made a slight occlusal adjustment on the lingual surface. The patient and parents were pleased with the appearance of the unglazed product. We polished, glazed, and added a slight white line on the buccal of #9 to mimic natural tooth #8. The crown was fired in the Ivoclar Programat Oven on e.max glazing setting. After a final try-in, the crown was cemented in place using variolink translucent base and catalyst. We cleaned off the excess cement, verified the final occlusal scheme, and captured a final periapical image verifying cement removal (Fig. 8).

Post-operative instructions were given. The patient and parents were advised to call immediately if there was sensitivity, swelling, questions or concerns. I spoke with the parents and checked on the patient one day and one week postoperatively. She was proud of her new tooth and said it felt "awesome" (Fig. 9).



Clinical Case Study



Testimonial:

Carestream Dental products helped me gather valuable clinical information, diagnose, monitor treatment status, and provide better care for this patient. The digital radiographs initially captured by the CS 8100 3D to evaluate the tooth were clear and beneficial to determine fracture and position of nerve tissue. This clarity allowed us to see the bone pattern and periodontal ligament space surrounding the damaged tooth. In addition, the 3D scan, taken at a 5 cm x 5 cm field of view and 300 voxels, allowed us to rule out buccal or palatal plate fractures before finalizing the treatment plan. The various voxel settings let us select the best exposure time to image the structures we desire to view. This would not have been possible in the past with a panorex or digital 2D radiograph system.

The fact that we were able to provide the patient and her parents with a three-dimensional CBCT of tooth #9 gave them the opportunity to see and understand what was going on under the surface; ultimately resulting in positive acceptance of the treatment plan. I find that the CS 8100 3D unit gives me an incredible level of detail with actual size images that I can view from any angle or cross-section to get the best possible diagnostic image. CS Solutions (CS 3500 intraoral scanner, CS Restore software and CS 3000 milling unit) allows my office the opportunity to fabricate same-day permanent restorations. My patients appreciate the fact that our office is staying up to date with new available technology and giving them a safer environment with less radiation.

Would you like to know more? Visit us on the web at www.carestreamdental.com or call **800.944.6365**.