

## CS 9300 System

# CBCT Assessment of Condylar Position During Class II Correction Using Fixed Appliances

Robert L. Waugh, D.M.D., M.S.

Treating skeletal mandibular deficiency in growing patients is complex for both patient and clinician. Far more important than aesthetics, if left untreated an overbite can lead to issues with the temporomandibular joints or sleep apnea. Careful timing of treatment and appliance removal is key to ensuring a successful outcome.

### Using Two-Dimensional X-rays to Examine a Three-Dimensional Joint

Two-dimensional panoramic and cephalometric X-rays are typically used to evaluate the condylar morphology. Ideal condylar position is generally acknowledged as when both condyles are centered and superiorly positioned in the joint spaces with the cartilage discs interposed between these articulating surfaces. However, the nature of the fibrocartilage of which the disk is composed does not provide much radiographic evidence, leaving only the condyles and glenoid fossae to hint at a patient's condylar position in the fossae. Even the corrected tomogram, which is typically considered superior to panoramic and cephalometric X-rays, cannot provide a 100 percent accurate view due to positioning issues and superficial structures.

When using two-dimensional technology, the typical Hebrst protocol involves empirical timing or clinical methods for timing appliance removal. For example, some Class II protocols call for removing appliances at a fixed point, i.e., at 12 months, which often includes some overcorrection and added time to lessen re-treatment needs

### Cone Beam Computed Tomography Confirms Early Removal of Appliance

However, I prefer comparing a pre-treatment condylar position CBCT scan from a CS 9300 with a progress scan. I've found that the Maia strategy<sup>1</sup> of obtaining a low-dose CBCT scan at eight months into treatment to assess condylar position remodeling confirms that 90 percent of my patients are ready to come out of their appliances at eight months.

The pre-treatment TMJ scan ( $T_0$ ) allows me to document any pre-existing TMJ conditions and the progress scan ( $T_1$ ) allows me to assess the condyle and fossae relationships for risk of relapse. Combining the condylar position information with the clinical presence of a Class I canine and posterior

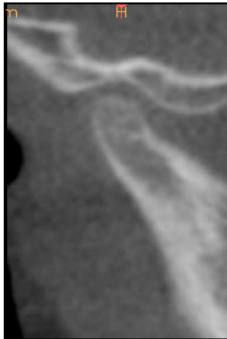

Robert L. Waugh, D.M.D., M.S.

Dr. Waugh has practiced orthodontics full time in Athens, Ga. since 1989 and is also an assistant professor at Georgia Regents University College of Dental Medicine's Orthodontic Residency program. He graduated from The Medical College of Georgia School of Dentistry in 1987 with both a D.M.D and a Masters in oral biology and was elected to OKU, dentistry's honor society. He earned his orthodontic certification and a second master's degree at Baylor University in 1989. In 2000 he was board-certified by the American Board of Orthodontics. Dr. Waugh has served as President of the Georgia Association of Orthodontists and is a member of the International and American Colleges of Dentists.



# Case Study

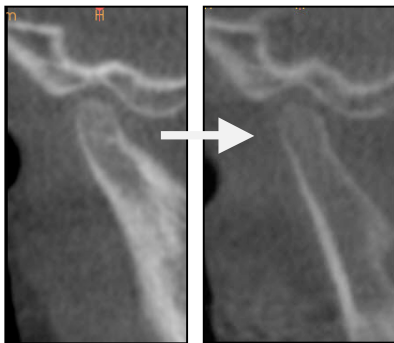


**Fig. 1:** “SS”—T<sub>0</sub> scan pre-treatment (cropped)

teeth in contact has proven to be a successful method of assessment for appliance removal with the least incidence of relapse.

The process involves a 17cm X 6cm field of view (FOV) scan from the CS 9300 at a 200 $\mu$  voxel size that captures both TMJs. The initial scan (Fig. 1) evaluates the patient’s condylar health and original positions in preparation for treatment. The entire scan is then submitted to my radiologist, Tony Lepain, R.T., for review.

Eight months after placing the Class II correction appliance, I rescan the TMJs and compare the T<sub>0</sub> and T<sub>1</sub> scans (Fig. 2). If both condylar heads are properly centered in the glenoid fossae while teeth are in maximum intercuspation, the Herbst appliance can be removed without risk of immediate relapse.

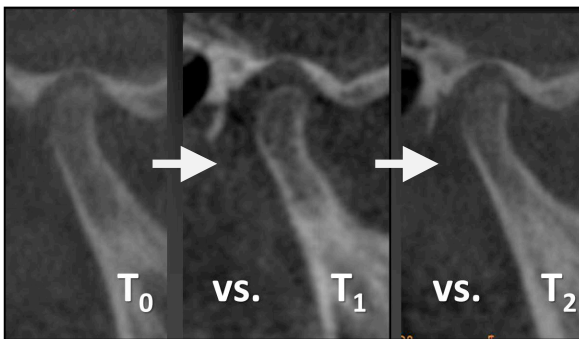


**Fig. 2:** “SS”—T<sub>0</sub> scan pre-treatment vs “SS”—T<sub>1</sub> at eight months

As previously mentioned, 90 percent of patients’ condyles are bilaterally reseated; they are ready to move forward in treatment, absent their appliances. For the other 10 percent of patients, using the same CBCT scan setting I reexamine their condylar positions at 12 months (T<sub>2</sub>), which almost always confirms treatment is complete (Fig. 3).

### “Predictable Outcomes”

For my busy practice to operate smoothly, I have certain systems in place to deal with the high-volume of patients. These initial CBCT scans are one of those systems. They provide a thorough and clean view of condylar anatomy and position, at low-risk to the patient, so that I can quickly determine which patients are the best candidates for an appliance. The benefit is I have predictable outcomes. Otherwise, do I really want to walk up to a patient and not *know* if they’re going to be corrected?



**Fig. 3:** “AJ”—Comparison of three scans (pre-treatment, eight months and 12 months)

Taking the initial CBCT scan also lets me screen for pathology early in the treatment process. The thoroughness of the T<sub>0</sub> scan—whole head scan, radiologist review—reassures me that I’m beginning treatment with a healthy joint. In two cases, I’ve caught degenerative arthritis during the initial scan.

Of course, my patients are perfectly happy to benefit from these systems and outcomes, too. By using low-dose CBCT protocols to examine treatment results at a point, the evidence shows an overwhelming majority

of patients are finished at eight months. We avert four additional months of discomfort and difficult oral hygiene and optimize treatment results.

To learn more about the CS 9300 please call **800.944.6365** or visit **carestreamdental.com** today.

