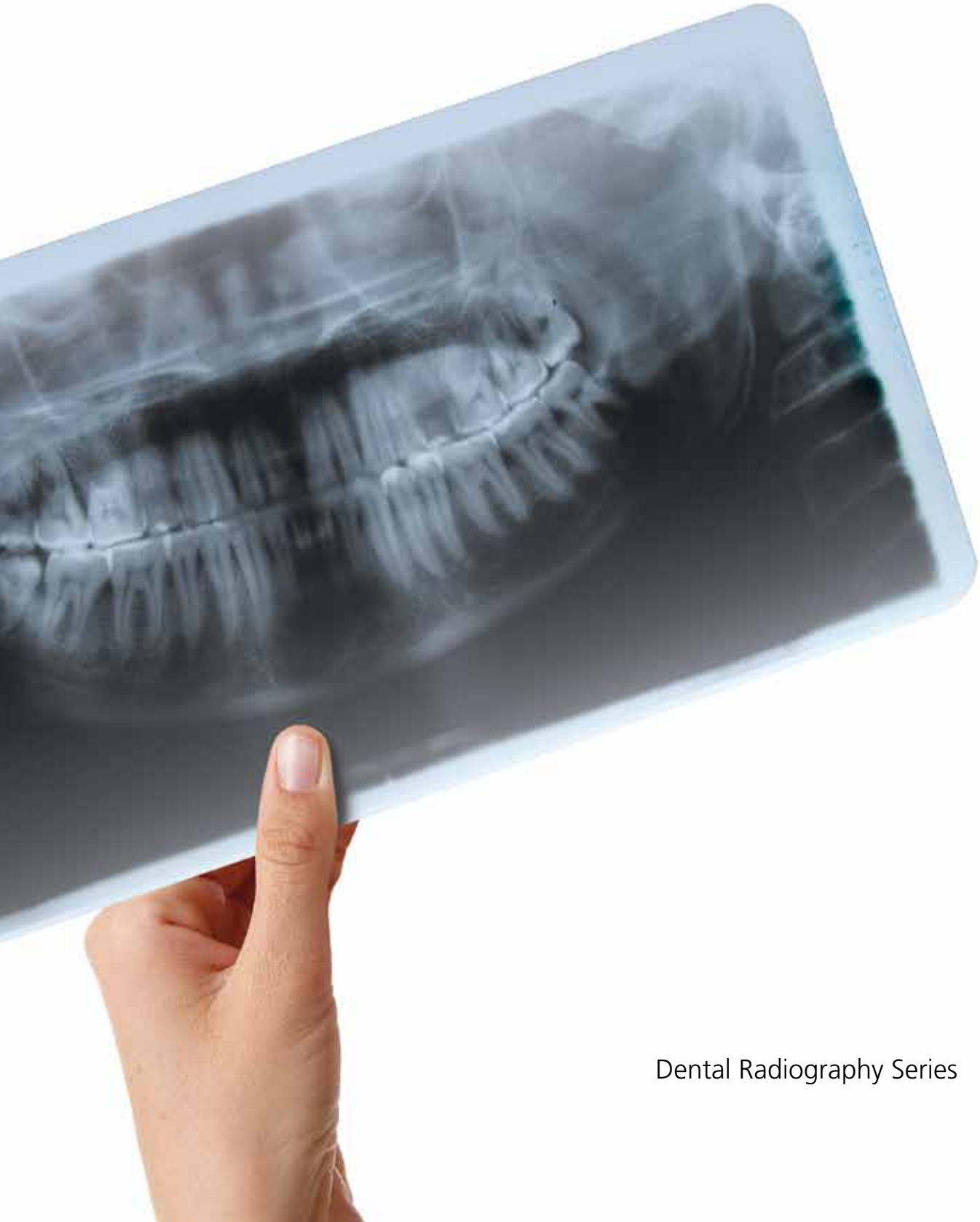



# Successful

Extraoral Radiography

Dental Radiography Series





# Content

Introduction . . . . .	5
Panoramic theory . . . . .	6
The Ten Steps . . . . .	9
Step 1: Loading the cassette . . . . .	10
Step 2: Setting exposure factors . . . . .	11
Step 3: Have patient remove jewelry, place lead apron on patient . . . . .	12
Step 4: Bite on rod . . . . .	14
Step 5: Adjust chin tilt . . . . .	15
Step 6: Position and close side guides . . . . .	16
Step 7: Have patient stand upright . . . . .	17
Step 8: Have patient swallow, place tongue in roof of mouth, and hold still . .	18
Step 9: Expose film . . . . .	19
Step 10: Processing . . . . .	19
Film theory . . . . .	20
KODAK Dental Systems recommended dental films and intensifying screens . . . . .	21
EKTAVISION screen-film system . . . . .	22



# Introduction

The panoramic radiograph continues to offer today's dentist a unique patient view; covering the entire dentition and surrounding structures, the facial bones and condyles, and parts of the maxillary sinus and nasal complexes. The equipment used to obtain panoramic radiographs has continued to improve with recent advances including automatic exposure and multiple image programs. However, to achieve a diagnostic panoramic image requires attention to ten basic steps in obtaining a panoramic radiograph.

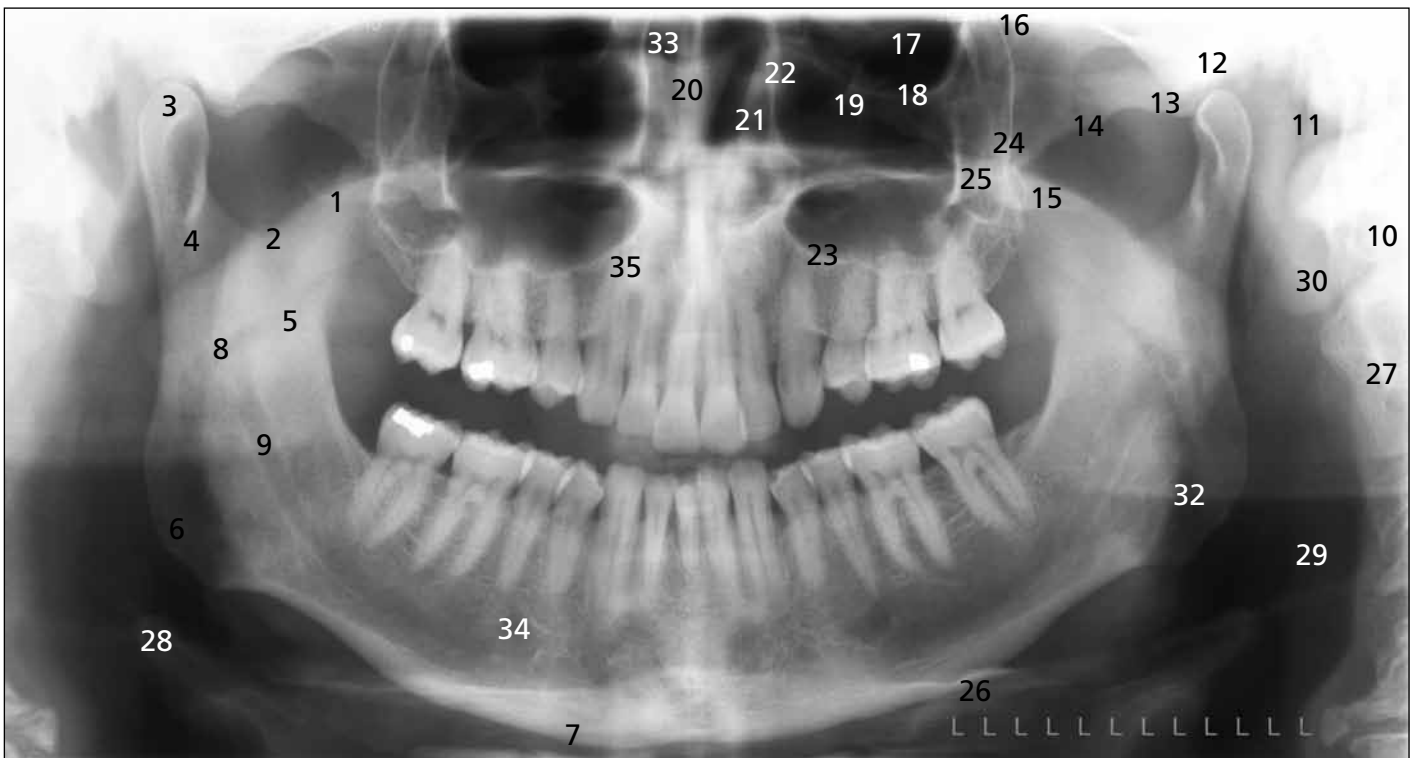
These steps are common to all panoramic machines, and when followed, will allow anyone to take a successful panoramic radiograph! This booklet will

address the problems and errors that may occur in the panoramic radiograph when mistakes are made at any of the ten basic steps.

This will allow the practitioner to determine from the radiograph the point at which the error occurred in the image creation process.

The booklet will then suggest possible solutions to the problem, based on this information. This will allow easy correlation of error with its correction, and give a better understanding of what caused the error. The result will be panoramic radiographs with the maximum diagnostic detail and information that the equipment and technique allows.

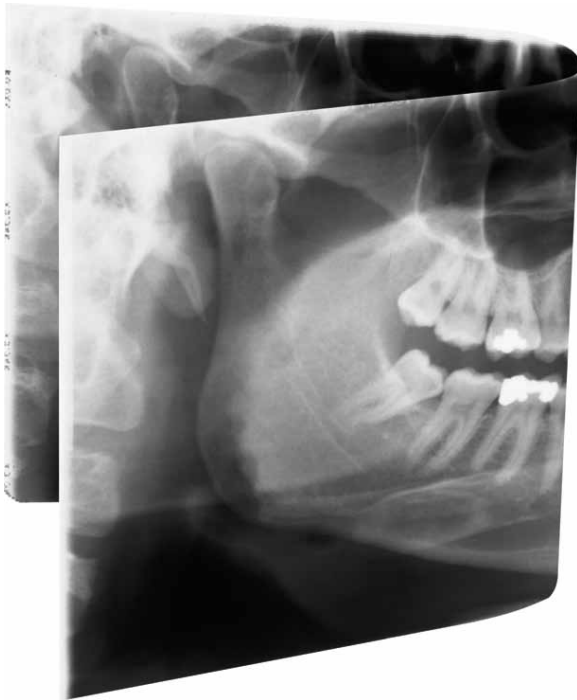## Panoramic landmarks



- |                                |                                       |   |
|--------------------------------|---------------------------------------|---|
| 1. Coronoid Process            | 14. Zygomatic Arch                    | 27. Cervical Vertebrae 1- 4   |
| 2. Sigmoid Notch               | 15. Pterygoid Plates                  | 28. Epiglottis  |
| 3. Mandibular Condyle          | 16. Pterygomaxillary Fissure          | 29. Soft Tissues of Neck (Look Vertically for Corotid Artery Calcifications Here) |
| 4. Condylar Neck               | 17. Orbit                             | 30. Auricle   |
| 5. Mandibular Ramus            | 18. Inferior Orbital Rim              | 31. Styloid Process   |
| 6. Angle of Mandible           | 19. Infraorbital Canal                | 32. Oropharyngeal Air Space   |
| 7. Inferior Border of Mandible | 20. Nasal Septum                      | 33. Nasal Air Space   |
| 8. Lingula                     | 21. Inferior Turbinate                | 34. Mental Foramen  |
| 9. Mandibular Canal            | 22. Medial Wall of Max. Sinus         | 35. Palatum durum   |
| 10. Mastoid Process            | 23. Inferior Border of Max. Sinus     |   |
| 11. External Auditory Meatus   | 24. Posterolateral Wall of Max. Sinus |   |
| 12. Glenoid Fossa              | 25. Malar Process                     |   |
| 13. Articular Eminence         | 26. Hyoid Bone                        |   |

# ■ Panoramic theory

Why is panoramic radiography inherently technique sensitive? Panoramic radiography is a modified type of tomography or image layer radiography. In panoramic radiography, the patient's dental arch must be positioned within a narrow zone of sharp focus known as the image layer or "focal trough". (Figure 1)



Teeth and structures lying outside this zone of sharp focus will exhibit blurring, distortion or other artifacts. Therefore, all panoramic machines will have some mechanism for properly positioning the patient's dentition within the focal trough. Because the trough can be quite narrow, as little as 3 mm in width in the anterior region, following the manufacturer's guidelines for proper patient positioning is critical in obtaining a quality radiograph.

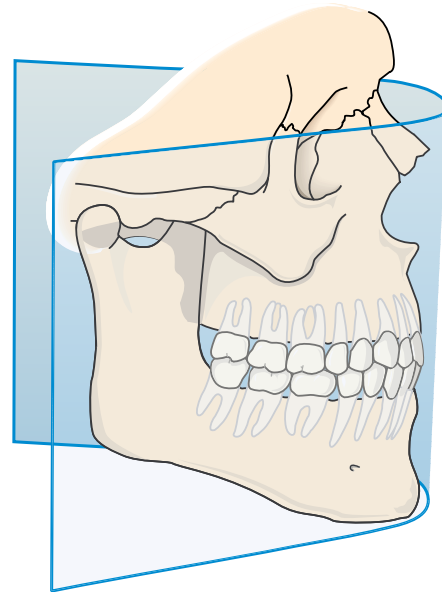


Figure 1

Magnification and X-ray tube focal spot size are two important factors in determining extraoral image quality (Figure A). Resolution, the ability of an imaging system to produce distinct images of closely spaced objects, is an objective measure of image quality, and is expressed in units of Line Pair per millimeter (LP/mm). As the theoretical resolution increases, so does the system's ability to reveal fine detail in the image.

The following chart (Figure B), plots resolution versus magnification for four X-ray tube focal spot sizes, and shows the limitations of two different film/screen combinations. The area of interest is between 120% and 160% in magnification typical of most panoramic and tomographic machines. The curves show conclusively that using the smallest focal spot possible and minimizing magnification decreases blurring or image unsharpness.

# Panoramic theory

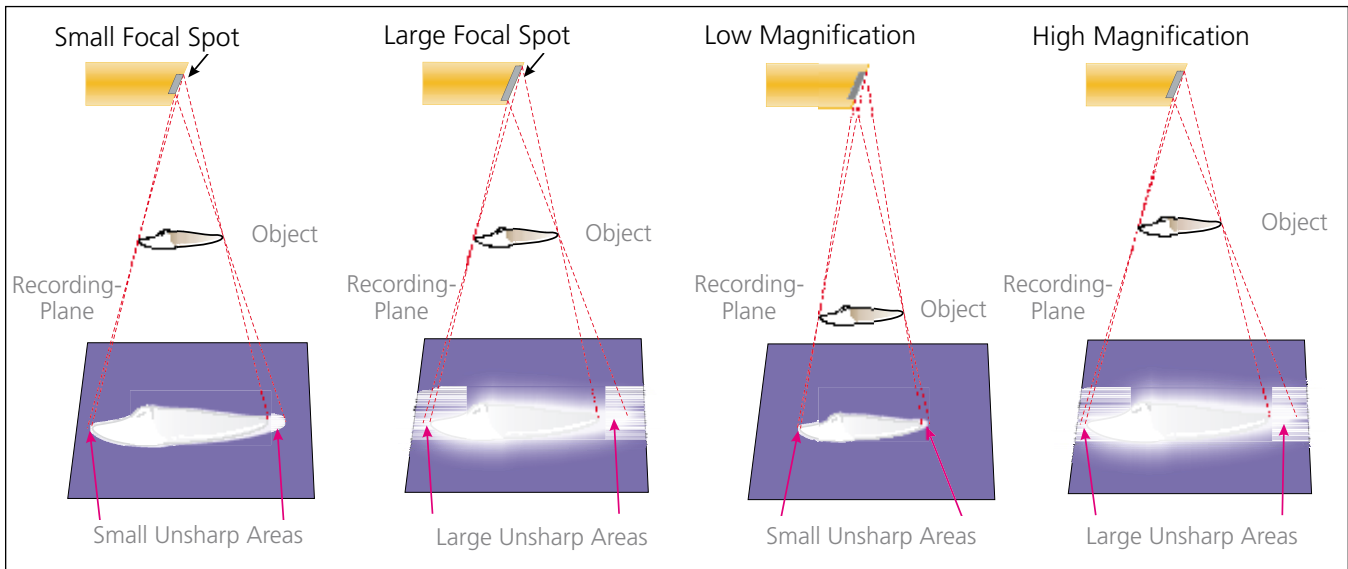


Figure A - Magnification and X-ray tube focal spot size

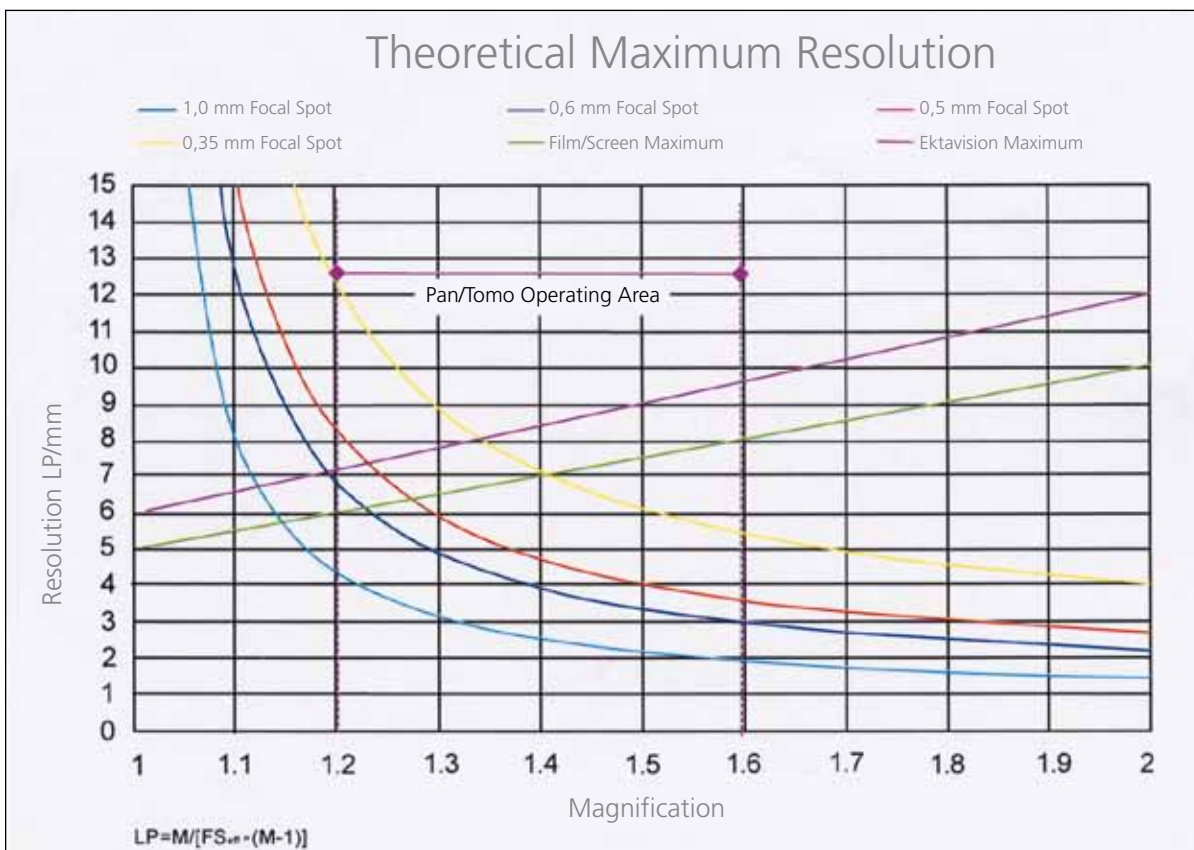


Figure B – Theoretical Maximum Resolution

Figure B – To calculate the resolution for a given device, select the magnification, read vertically up the chart, until it intersects the focal spot line of the device. Read horizontally across the chart until it intersects the resolution axes.

The intersection of these two lines will demonstrate the theoretical maximum resolution. The actual resolution is limited by film screen combination, and un-sharpness due to the motion of the panoramic unit.



# I The ten steps

## The ten steps

There are ten basic steps in taking a panoramic radiograph. These steps will apply to almost any panoramic machine (See Table 1). It is important to know how they affect the outcome of the radiographic process. When problems occur at any of the ten steps they will cause unique errors on the resulting radiographs. When recognized, these errors are easy to correct.

### TEN STEPS IN PANORAMIC RADIOGRAPHY

1. Load cassette.
2. Set exposure factors.
3. Have patient remove jewelry; place apron on patient.
4. Have patient bite on bite rod.
5. Adjust the chin tilt.
6. Position the side guides.
7. Have the patient stand up straight.
8. Have patient swallow, place tongue in roof of mouth, and hold still.
9. Expose the film.
10. Process the radiograph.

Table 1 – Ten steps in panoramic radiology

# The normal panoramic radiograph

Before discussing various errors that can occur, it is important to know what a normal panoramic radiograph should look like. In a good panoramic radiograph the mandible is “U” shaped, the condyles are positioned about an inch inside the edges of the film and 1/3 of the way down from the top edge of the film. The occlusal plane exhibits a slight curve or “smile line,” upwards. The roots of the maxillary and mandibular anterior teeth are readily visible with minimal distortion. Magnification is equal on both sides of the midline (Figure 2).

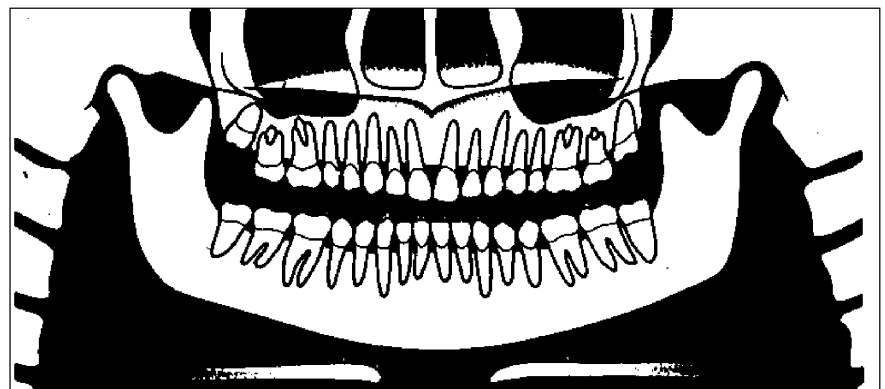
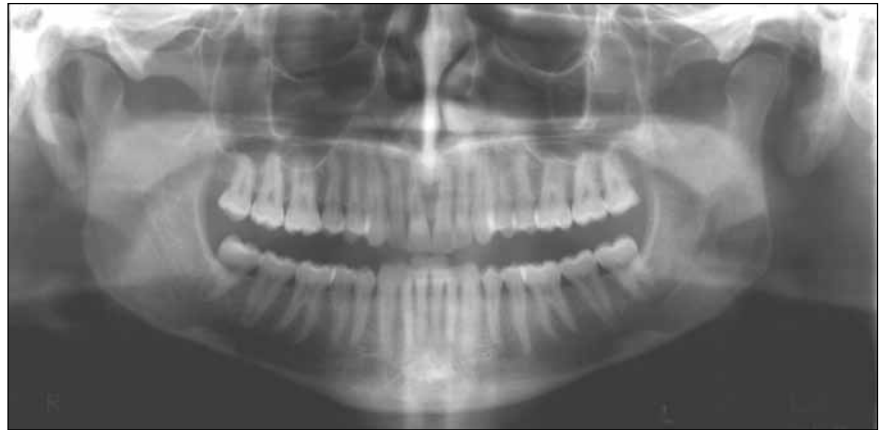

Figure 2a,b – Normal panoramic radiograph

## Step 1: Loading the cassette

In panoramic radiograph an extraoral film holder is used, which consists of two fluorescent screens with film sandwiched in between them. Each screen fluoresces when struck by X-rays forming an image on the film. These screens are 10-60 times more sensitive to X-rays than film, resulting in the very low dose of radiation required to make an image. New advances in screen technology such as the KODAK Ektavision system provide even sharper images without as much blurring and scatter as previous systems. There are several common errors seen in the loading and use of cassettes (Table 2) (Figures 3, 4, 5, 6).

Problem	Cause	How to correct	Hints
Overall grayness or blackness along one edge or corner of film (fog)	Damaged cassette (light leak) or film exposed to light	Tape edges of soft cassette, replace damaged hard cassette	Cassettes should be inspected regularly for light tightness
Little or no image is visible on film	Screens reversed	Replace screens properly	Dull surface of screen should face film, not shiny
White streaks on image	Damaged (scratched) screens	Handle screens carefully	Use screen cleaning solutions and soft cloth to clean screens
Black marks, round clusters or lightening bolt	Static electricity	Avoid too rapid removal of film from cassette	Use of antistatic mats or humidifier can reduce static
Multiple images	Double exposure	Remove film from cassette after each exposure	Store unexposed and exposed cassettes separately

Table 2 – Cassette Problems

# The normal panoramic radiograph

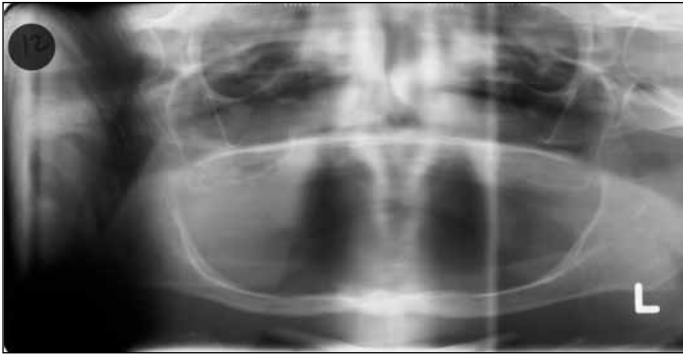

Figure 3 – Light leak from torn cassette

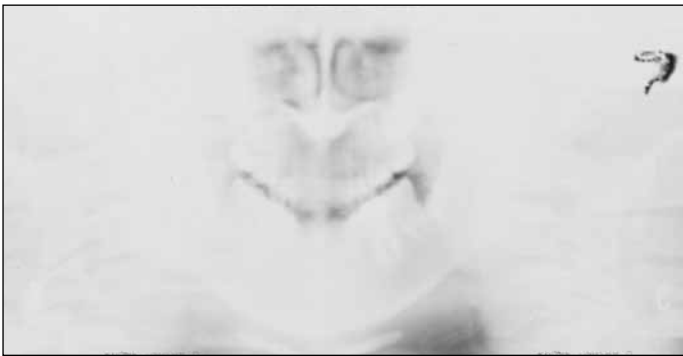

Figure 4 – Screens reversed

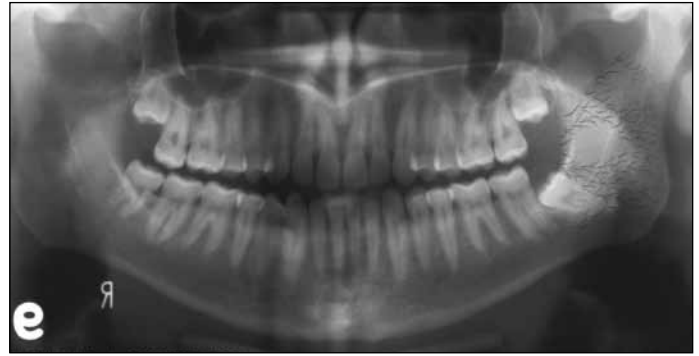


Figure 5 – Static electricity over L ramus

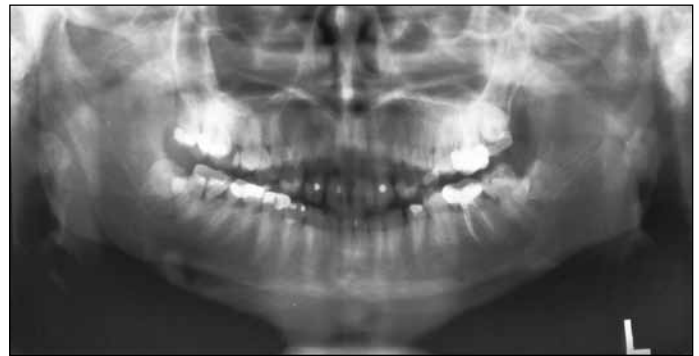

Figure 6 – Double exposure

## Step 2: Setting exposure factors

Many newer panoramic machines set exposure factors automatically by reading a small portion of the X-ray beam at the start of the exposure. With most panoramic machines, though, exposure must be set based on the patient's size or age. Usually, icons of small, medium, or large patients are used. Since the patient's bone density is not always related to their physical size, a better guide is to look at the patient's wrists or ankles. Thick wrists can imply heavier bone density; other factors to consider are age, whether the patient is edentulous, and obesity. Common exposure errors are illustrated in Table 3 (Figure 7).

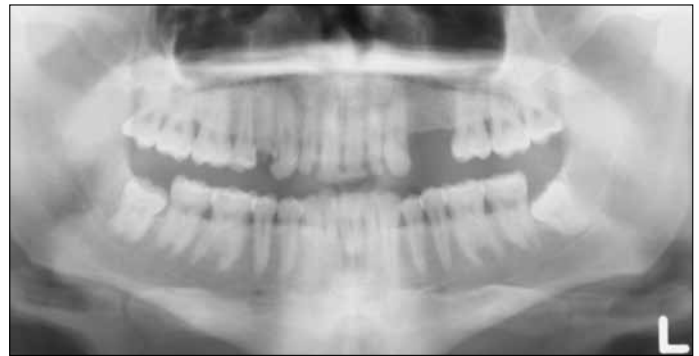

Figure 7 – Underexposure, note light, washed out image

Problem	Cause	How to Correct	Hints
Light, pale film with few dark areas	Too little exposure	Increase mA or kV or use next higher setting on machine	Also rule out worn-out or reversed screens
Dark film with loss of details, amalgams and unexposed areas are still clear	Too much exposure	Decrease machine settings	Don't confuse with film fogging, which is an overall grayness to film

Table 3 – Exposure errors

# The normal panoramic radiograph

Problem	Cause	How to correct	Hints
White opacities on film; little or no image is visible on film	Ghosts of metal jewelry	Remove prior to exposure	Watch out for necklaces
White opacity in palate	Tongue bar	Remove prior to exposure	Image is projected high onto palate instead of in floor of mouth
White opacity at bottom of film shaped like inverted "V" or "shark fin"	Lead apron above collar line and in X-ray beam	Adjust and properly place apron	Watch for bunching at back of neck

Table 4 – Jewelry, apron artifacts

## Step 3: Have patient remove jewelry, place lead apron on patient

Prior to exposure, the patient must remove all jewelry from the head area. The panoramic exposure encompasses the whole head. Earrings, necklaces, or other jewelry, such as tongues bars or nose rings will be visible on the radiograph.

Unique to the panoramic radiograph is the formation of "ghost" images. These images result when an object is imaged twice, once on the normal side of the center of beam rotation, and once on the opposite side. "Ghost" images are easily identified as they are on the opposite side of the real image, higher on the film, and are streaked horizontally. They can be mistaken for pathology when they fall in the area of the sinus. If a lead apron is used during the exposure, it must be properly placed. Special panoramic aprons should be used that cover the back of the patient and the shoulder area. The apron must not extend above the collar or it will be imaged on the film as an opaque "shark fin" artifact. This is due to the angle of the panoramic X-ray beam, which comes from below at approximately a 7-degree angle (Table 4) (Figures 8, 9, 10).

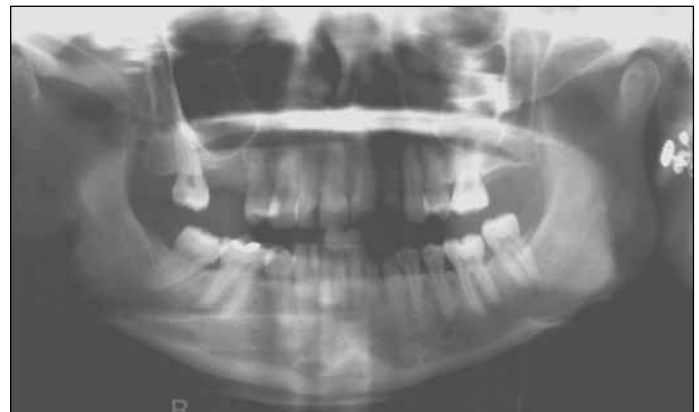

Figure 8 – Ghost of earring over left max sinus

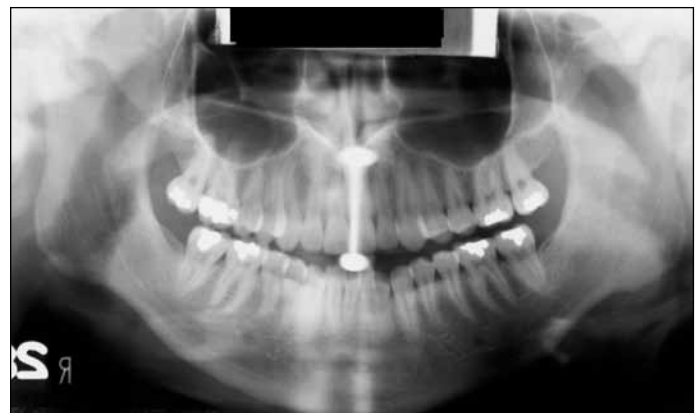

Figure 9 – Tongue bar projected over palate

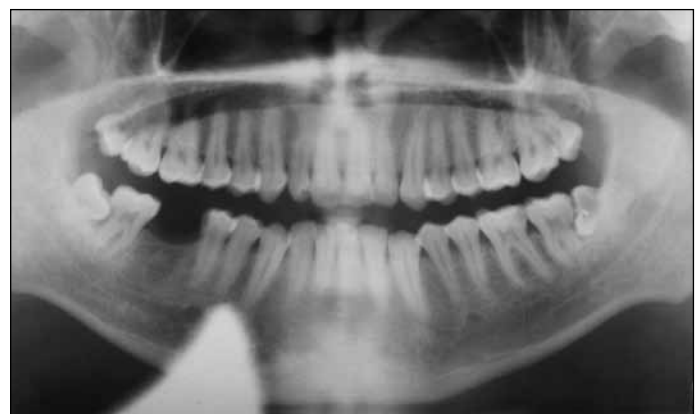

Figure 10 – Lead apron artifact

# | Patient positioning

The next few categories of errors are based on patient positioning problems. Most panoramic machines offer some type of positioning guides such as lights or plastic guides to position the patient along 3 major axes: anterior-posterior (too far forward or back), vertically (alartragus, Frankfurt plane, or cantho-meatal lines), and midsagittal alignment (patient twisted or rotated) (Figure 11).

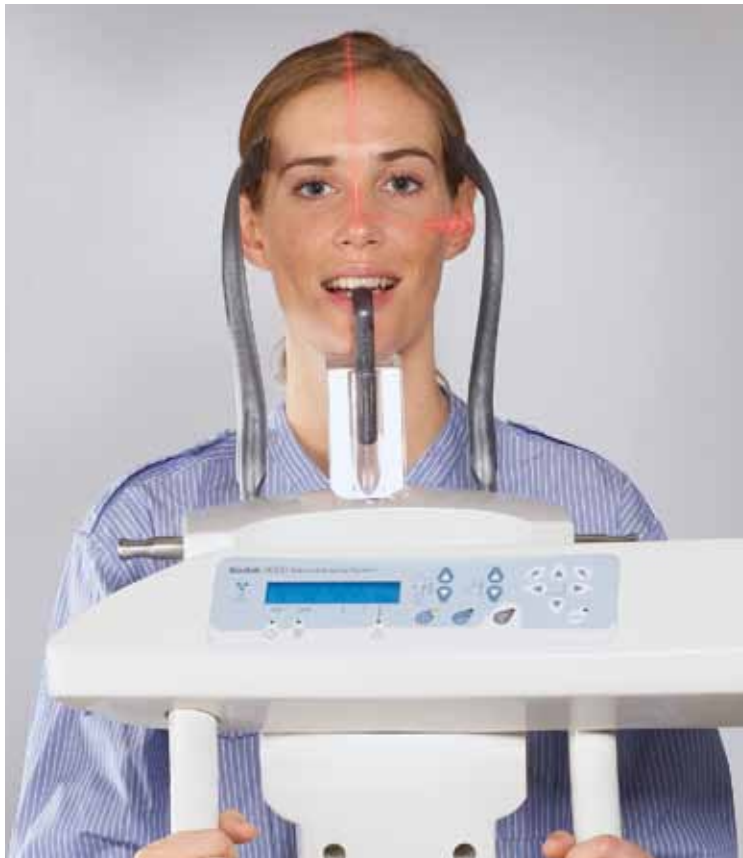

Figure 11 – Positioning guides; note the bite rod, head guides, and aiming light

# ■ Patient positioning

## Step 4: Bite on rod

Most panoramic machines use a bite rod made of plastic with small grooves to position the patient's anterior teeth in the focal trough. Most machines also offer an edentulous guide that is placed against the patient's chin or under the nose. These guides are also useful in partially edentulous cases as well, and failure to use them can cause anterior-posterior errors.

Other causes of patients being too far forward or back in the focal trough are anterior malocclusions such as bimaxillary protrusion. Most machines offer a correction for these cases. Many machines offer an aiming device centered on the mandibular cuspid, as it is considered to be more indicative of the patient's skeletal position (Table 5) (Figures 12,13).

Problem	Cause	How to correct	Hints
Anterior teeth blurry, too small and narrow, spine visible on sides of film	Patient biting too far forward on bite rod	Make sure anterior teeth are located in grooves on rod	Make sure mandibular incisors are in groove also, and bite rod is not being bent forward
Anterior teeth blurry and wide, ghosting of mandible and spine, condyles close to edge of film	Patient is biting too far back on rod or not at all	Make sure anterior teeth are located in grooves on rod	If anterior teeth are missing use edentulous guide

Table 5 – Anterior positioning errors

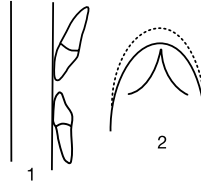
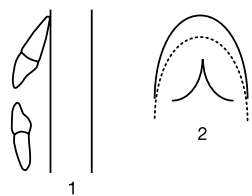
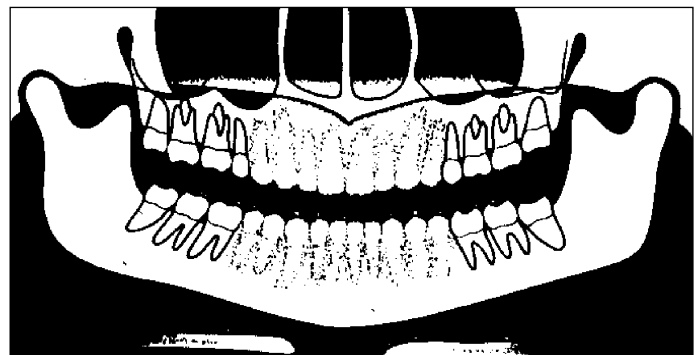
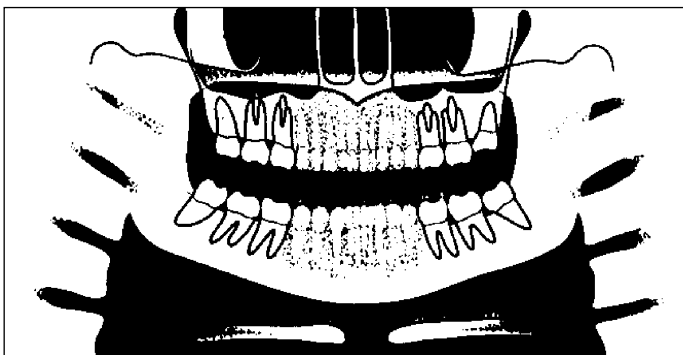
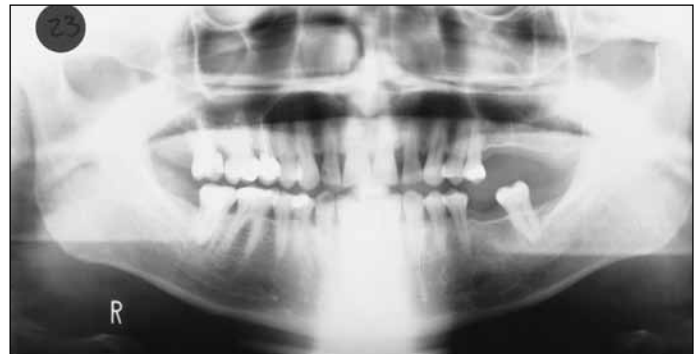
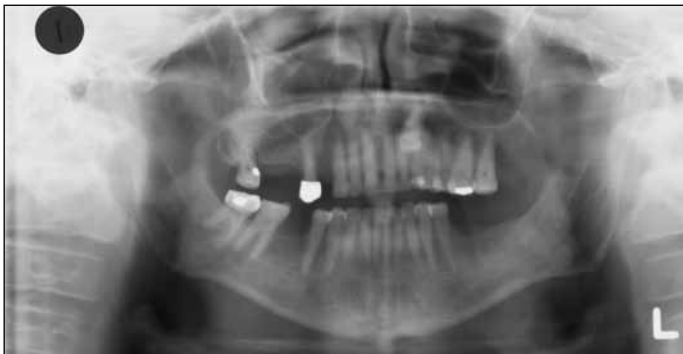
Figure 12 a,b – Patient too far forward; note spine superimposed over rami, blurring, and narrowing of anterior teeth

Figure 13 a,b – Patient too far back; note ghosting of mandible and spine, condyles pushed to outside of film, blurring and widening of anterior teeth

# ■ Patient positioning

## Step 5: Adjust chin tilt

In the panoramic radiograph the patient should be looking slightly down at a spot on the floor approximately 8 feet in front of them. This elevates the posterior palate so it does not overlap the apices

of the maxillary teeth in the final image. This is often referred to as “chin tilt.” Having the patient’s chin tipped too far down is the most common panoramic error (Table 6) (Figures 14,15).

Problem	Cause	How to correct	Hints
Roots of lower incisors blurry, mandible shaped like a “V”, too much smile line, condyles at top of film, spine forms arch or “gazebo” effect	Patient’s chin is tipped too far down	Reposition using proper guidelines for that machine, such as alartragus line	Make sure patient does not have unusual occlusal plane orientation
Maxillary incisors blurry, hard palate superimposed on roots, flat occlusal plane, mandible is broad and flat, condyles at edge of film	Patient’s chin is tipped too far up	Reposition using proper guidelines for that achine such as alartragus line	Make sure bite rod remains seated in its guide

Table 6 – Chin tilt errors

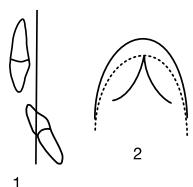
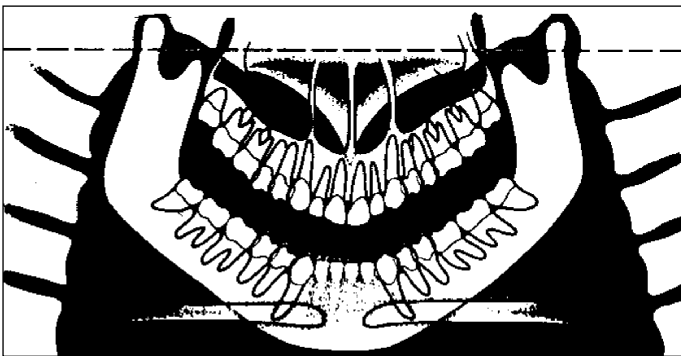
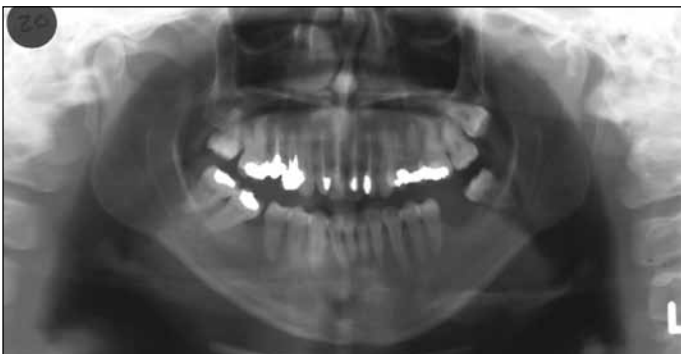

Figure 14 a,b – Chin tipped down; note V-shaped mandible, extreme smile line, arching of spine at top of film, condyles placed high on film, and streaking of the hyoid bone over the mandible

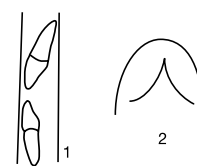
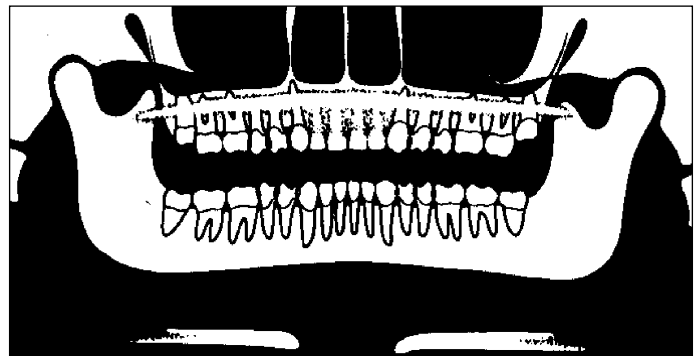
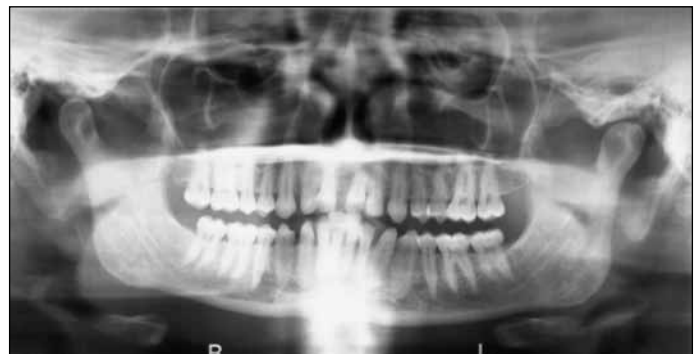

Figure 15 a,b – Chin up too high; note flattened occlusal plane, palate superimposed on maxillary tooth roots, and broad flat mandible

# ■ Patient positioning

## Step 6: Position and close side guides

All panoramic machines will have guides or positioning lights to align the patient's midsagittal plane. It is important that the patient be looking straight ahead with no tip or tilt to the head. Side guides may be used

and may come from either the top or the bottom of the machine. When the patient's head is twisted, it is similar to being too far forward on one side and too far back on the other (Table 7) (Figure 16).

Problem	Cause	How to correct	Hints
Teeth are wide on one side, narrow on other side of midline; ramus is wider on one side than the other; uneven pattern of blurring throughout arch; nasal structures not clear	Patient's head is twisted in machine causing midline asymmetry	Reposition using proper guidelines for that machine	Make sure patient doesn't try and look towards technician, but straight ahead. Always use frontsurface mirror on machine to check alignment
Condyles are not equal in height, nasal structures distorted	Patient's head is rotated in machine (tipped)	Reposition using proper guidelines for that machine	Make sure patient's head remains level through ears

Table 7 – Head twist errors

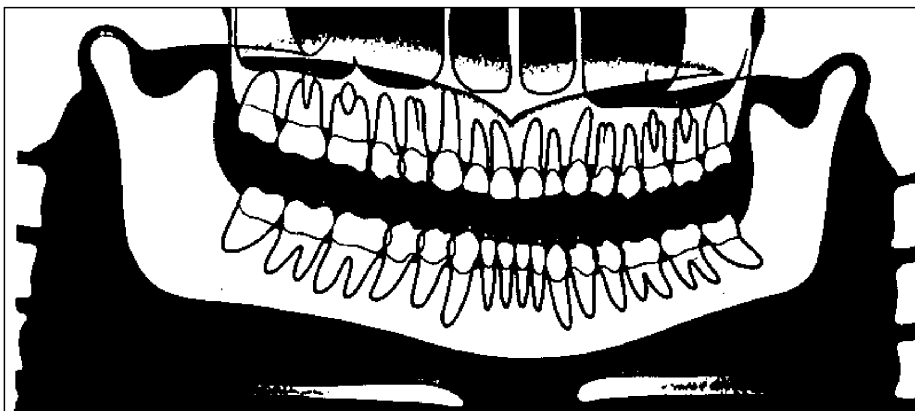
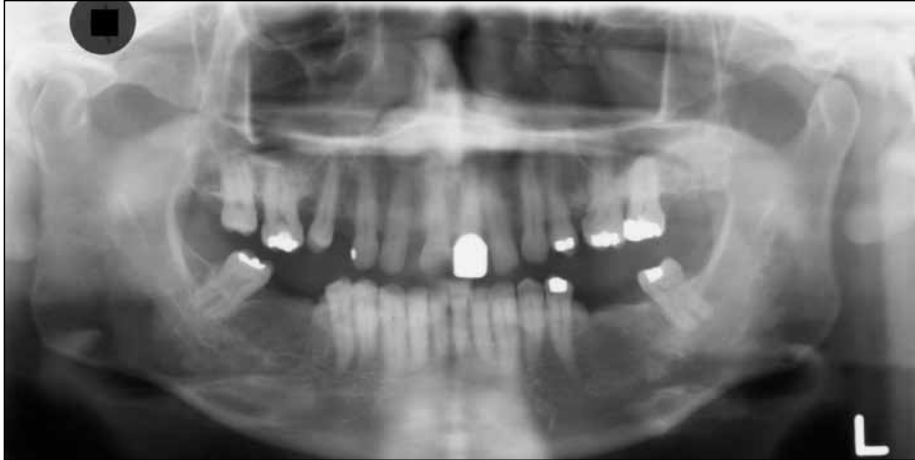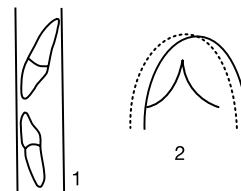


Figure 16 a,b - Head twisted; note uneven width of rami, unequal magnification of teeth, and condyles



# ■ Patient positioning

## Step 7: Have patient stand up straight

The patient must be standing up straight to prevent arching of the neck (slumping). The best method of achieving this is not to allow the patient to reach forward to the bite stick or chin rest. Have the patient take a step forward after they are biting the rod. They

should feel like they will fall backward if they let go of the hand-holds. This will avoid problems with the cassette hitting the shoulders and spinal ghosting (Table 8) (Figures 17, 18).

Problem	Cause	How to correct	Hints
White tapered opacity in middle of image	Ghost of spinal column due to slumping	Have patient take a step forward and straighten neck	Don't allow patient to reach forward into machine; make them step forward
Dark vertical line extending from top to bottom edge of film	Cassette hit shoulder and temporarily stopped	Straighten neck as above. Check apron for interference	Have patient keep elbows tucked in to sides to reduce shoulder height

Table 8 – Slumping errors

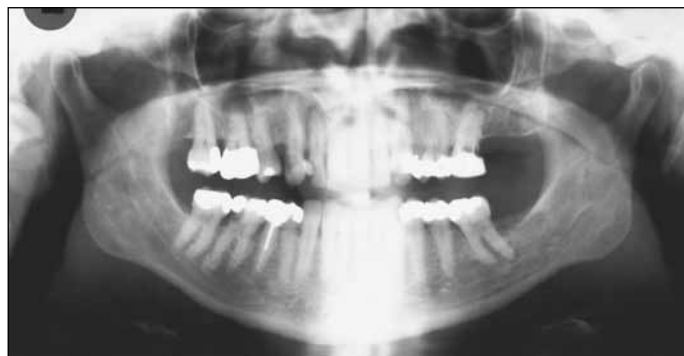

Figure 17 a,b - Slumped; note the white spine shadow in midline

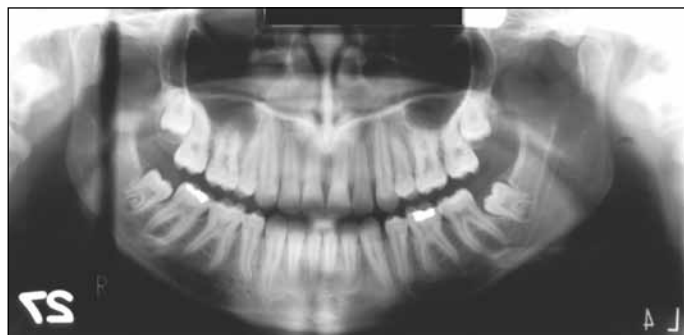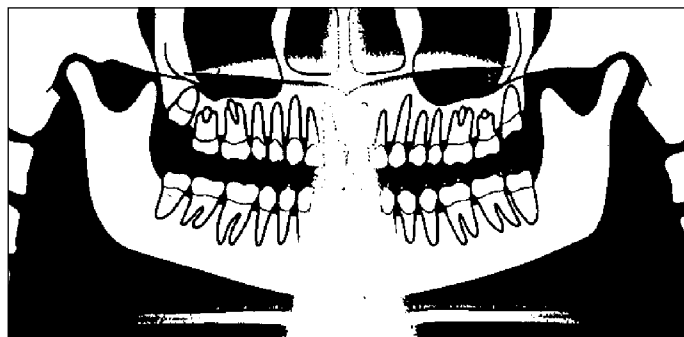


Figure 18 - Cassette hit patient's shoulder; note dark vertical stripe on film

# ■ Patient positioning

**Step 8: Have patient swallow, place tongue in roof of mouth, and hold still**

Just before the exposure is made, the patient is instructed to swallow, place the tongue in the roof of the mouth, and hold still during the exposure. Failure to do these things can result in patient movement artifacts or airway obscuring vital portions of the image. In particular, not placing the tongue in the roof of the mouth results in a large airway shadow directly over the roots of the maxillary teeth (Table 9) (Figures 19, 20).

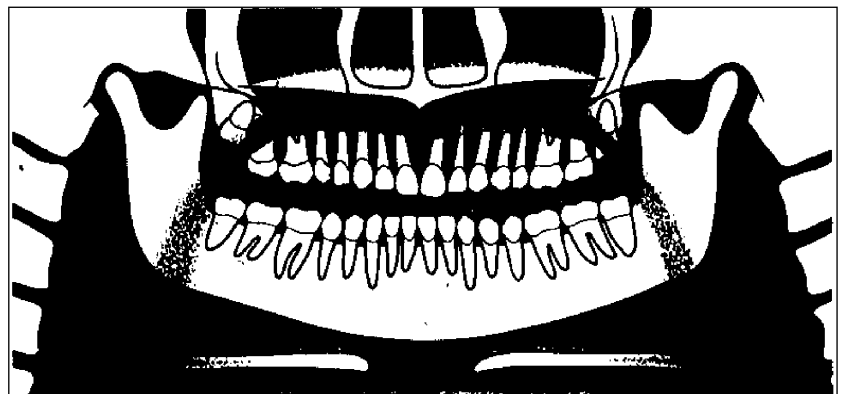
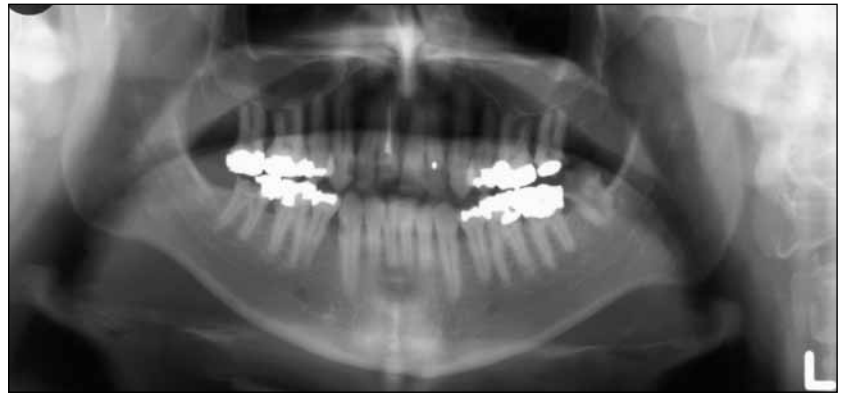
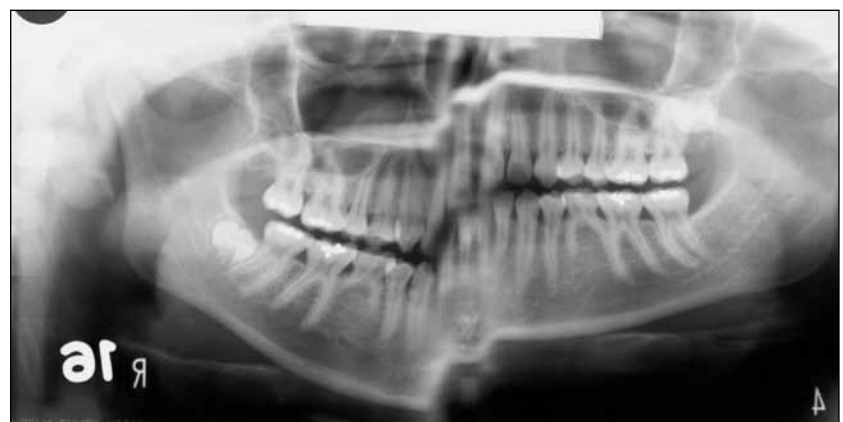

Figure 19 a, b - Tongue down during exposure; note shadow of air space over roots of maxillary molars, airway space over rami

Problem	Cause	How to correct	Hints
Large, dark shadow over maxillary teeth between palate and dorsum of tongue	Patient's tongue not in roof of mouth	Instruct patient to place tongue in roof of mouth prior to exposure	Having patient swallow first can make it easier for them to obtain proper tongue position
Portions of radiograph are blurred; large step defects in inferior border of mandible	Panoramic exposure takes approx. 15 seconds. Patient moved during this time	Instruct patient to hold still prior to exposure	Tell patient exposure will last 15 seconds, so that they expect it

Table 9 - Tongue; movement errors

Figure 20 - Patient movement; note step defect in inferior border of mandible



# Exposure and processing

## Step 9: Expose film

Problems during exposure are primarily due to machine or operator errors including letting go of exposure button temporarily (not possible with most recent machines), changing exposure settings during the exposure, or not having the cassette properly inserted in the machine. Cassettes must be inserted with the smooth, flat side facing the X-ray tube (Table 10) (Figure 21).

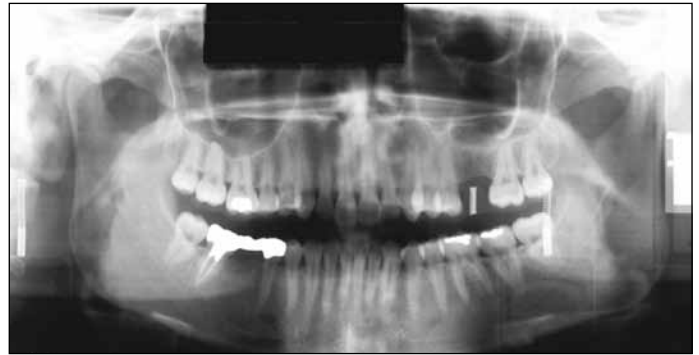

Figure 21 - Cassette placed backwards in machine, note images of springs on film. Right and left sides will be mislabeled when this happens. Image will be light.

Problem	Cause	How to correct	Hints
White vertical line on film running from top to bottom edge of film	Exposure stopped briefly, probably due to letting go of exposure button	Hold exposure button down firmly during exposure	Modern machines will return to start position if this happens
Images of springs or rectangular radiolucencies visible on film	Cassette was placed in machine backwards	Label tube side; place lead foil "X" on back side of cassette	Left and right will be reversed on film if this happens

Table 10 - Errors during exposure

## Step 10: Processing

Panoramic errors during processing are no different than with intraoral film. Spent or depleted chemistry will lead to washed out, poor quality images. Panoramic films can normally be processed in standard dental automatic processors. However, if a daylight loader is used it must contain a red filter rather than an amber one. Panoramic film is sensitive to green light and the standard amber filter does not block this wavelength.

If large volumes of panoramic radiographs are being processed such as in an oral surgery practice, consideration should be given to the purchase of a Kodak X-OMAT processor. These processors are designed to handle the size and surface area of the panoramic radiograph (1 panoramic radiograph is equivalent to a full-mouth series in terms of surface area and chemistry usage) without rapid chemistry

depletion. In addition, they supply a dry film in only 90 seconds. A small X-OMAT tabletop processor costs only slightly more than a standard dental automatic processor (Table 11) (Figure 22).

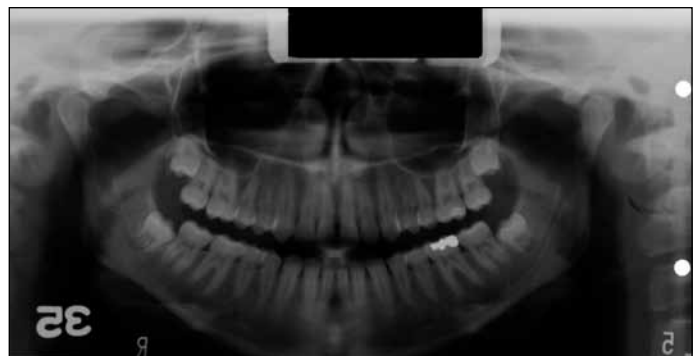

Figure 22 - Fogging of film; panoramic film requires a Kodak GBX-2 safelight filter

Problem	Cause	How to correct	Hints
Thin, washed-out images	Depleted chemistry	Replenish more frequently	Consider X-OMAT processor
Fogged film, overall gray or very dark film	Improper filter in daylight loader	Use red filter or cover viewing area on daylightloader	You can use cardboard to cover filter area while loading panoramic film

Table 11 – Processing errors

# Film theory

## Film theory – image receptor

The image receptor in extraoral radiography is a combination of two intensifying screens with a film in between, all of which are enclosed in a protective light-tight container called a cassette. A cassette can be soft or rigid. Each intensifying screen contains phosphor layer that fluoresces when activated by x-radiation which has penetrated the patient and the cassette. This fluorescent glow is what exposes the film. This exposure method differs from conventional intraoral

radiographs in which the x-rays directly expose the film. Film used in panoramic imaging is 10-60 times more sensitive to fluorescence than to X-rays; therefore, the amount of radiation needed to produce a high-quality film is less when using screens. As the X-ray beam and image receptor encircle the patient, the image is recorded on the film in vertical increments, which are restricted by the narrow beam and collimation.

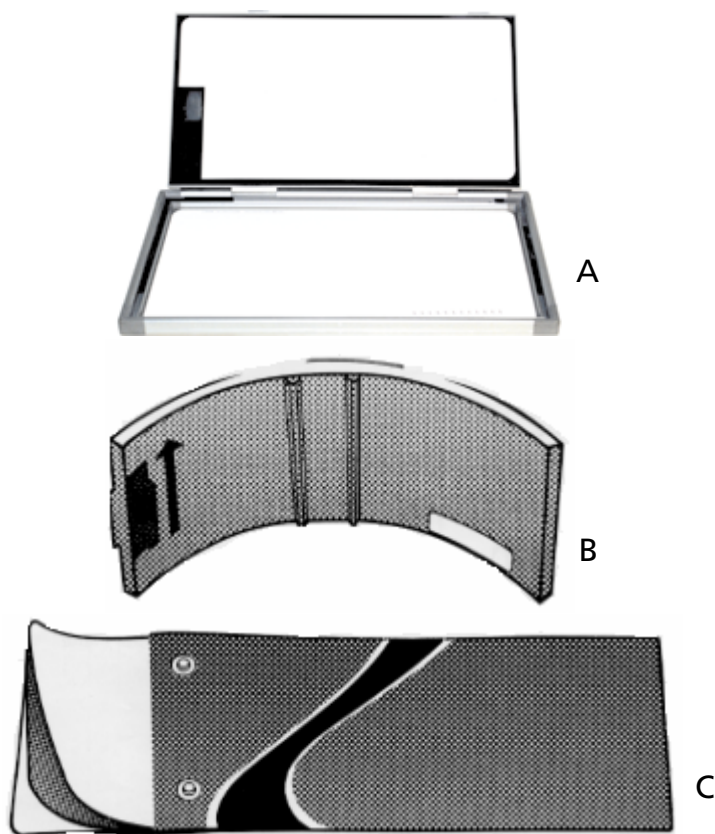


Figure 23 – Film Cassettes

## Film cassettes

Film cassettes, Figures A and B, are rigid cassettes. In a rigid cassette, the intensifying screens are attached to the inside cover and base of the cassette. When the panoramic film is placed in the cassette, it lies in-between the screens. Figure C is a flexible cassette that has an opening at one end, creating a pouch. The panoramic film is placed between two removable, flexible intensifying screens, which are then slid into the pouch.

## Screen / film combinations and speeds

Screen/film combinations come in different speeds. The faster the system speed, the lower the radiation dose to the patient. The approximate relative speeds and sensitivities of Kodak screen-film combinations are shown in Tables 12 and 13. Screens and films also vary by the type of light that they react to. Some react to ultraviolet light, others react to blue light, still others to green light. Table 12 presents values for green-emitting

Lanex and Ektavision screens and green-sensitive films. Table 13 presents values for ultraviolet-emitting Kodak X-Omat screens and blue-emitting calcium tungstate screens with blue-sensitive films. Screens and films are not interchangeable. It is important to use a blue-emitting screen with a film that is blue sensitive and a green-emitting screen with a film that is green sensitive.

# KODAK Dental Systems recommended dental films and intensifying screens

## Green-sensitive films and rare earth screens

Table 12

KODAK Film	KODAK EKTAVISION Imaging Screens and LANEX Screens
EKTAVISION G Screen-Film Speed 400	Provides high-contrast, sharp images for excellent detail when paired with EKTAVISION Imaging Screens. <b>Application:</b> panoramic, TMJ, cephalometric exams
T-MAT G/RA Screen-Film Speed 400*	Provides high-contrast, detailed images of bone and intervening tooth structures while retaining good soft tissue visibility when used with LANEX Regular or Medium Screens. <b>Application:</b> panoramic, TMJ, cephalometric exams
T-Mat L/RA Screen-Film Speed 400*	Provides wide latitude for good imaging of soft tissue areas of facial profile while providing good bone and tooth structure detail when used with LANEX Regular or Medium Screens. <b>Application:</b> cephalometric exams

\* System speed when used with LANEX Regular Screens and one film.  
System speed when used with LANEX Medium Screens and one film is 280.

## Blue-sensitive films and X-OMATIC REGULAR Screens

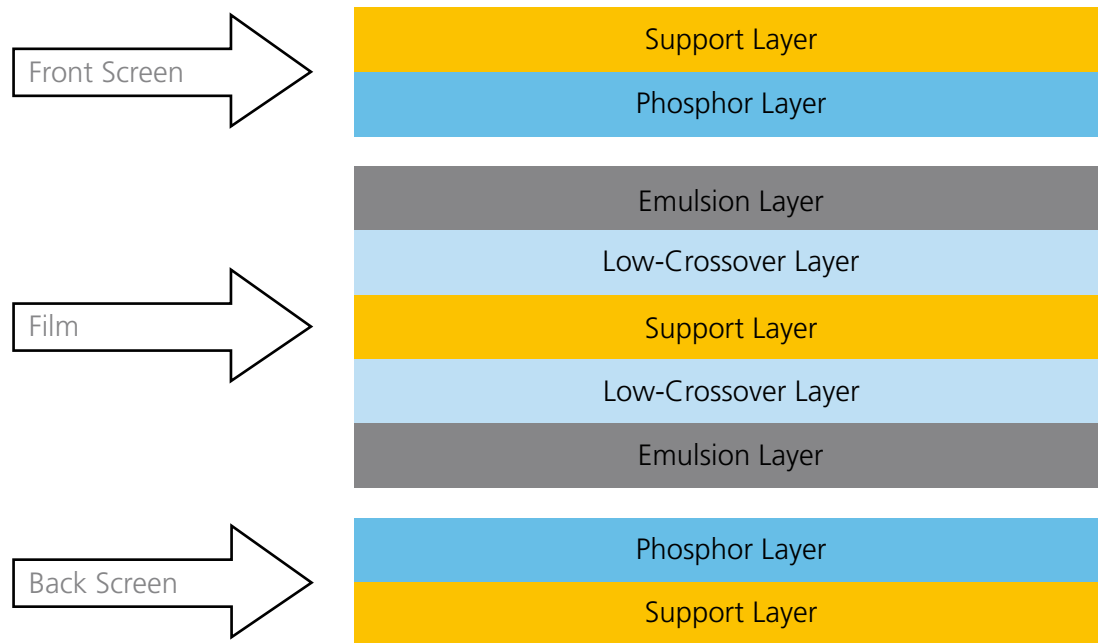
Table 13

KODAK Film	KODAK X-OMATIC REGULAR Screens
X-OMAT DBF Screen-Film Speed 200	Provides excellent diagnostic detail when used with X-OMATIC Regular Intensifying Screens. <b>Application:</b> panoramic, TMJ, cephalometric exams

If the systems are mixed (e.g., using KODAK T-MAT Film with KODAK X-OMATIC Screens), loss of density and contrast will result, and is absolutely not recommended.

# EKTAVISION screen-film system

## Cross-section diagram of the EKTAVISION G Screen-Film System



## Exposure settings

The average kV and/or mA setting is recommended by the film and unit's manufacturer, but can vary from patient-to-patient due to size, dentition, etc. In panoramic radiography, the exposure time is fixed by the time required to complete one full excursion of the

assembly. There are other factors that can affect the average exposure setting that is recommended by the equipment manufacturer. A summary of some of these factors is listed in Table 14.

## List of common factors that affect exposure

Table 14

Factors to Consider	Exposure Setting
Obese patient	Use the next highest kV or mA setting
Patient with large bone structure	Use the next highest kV or mA setting
Patient with small bone structure	Use the next highest kV or mA setting
Patient with small bone structure	Use the next lower kV or mA setting



# | Would you like to know more?

For more information, call **800-933-8031** or visit  
**[www.carestreamdental.com](http://www.carestreamdental.com)**



Carestream Dental

©Carestream Health, Inc. 2011.  
The Kodak trademark and trade dress are used under license from Kodak.