

INTERNATIONAL JOURNAL

# DIGITAL\_DENTAL\_NEWS



REPRINT

- Three-dimensional digital radiography in dental application

# Three-dimensional digital radiography in dental application

Dr. Herbert Martin

**After the launch of the first computed tomography scanners developed specifically for dentistry in 1996, this technology was predominantly restricted to large imaging centers and diagnostic clinics. Previously in spiral CT, the x-ray tube moves around the patient, who is sitting inside the circuit. During movement, the tube emits a theoretically two-dimensional, fan-shaped ray beam. From these data of the separately captured discoidal volumes, the computer generates a three-dimensional image. In contrast, digital volume tomography (DVT) uses a three-dimensional, cone-shaped ray beam and a two-dimensional flat-panel detector.**

Due to this technology, a single rotation around the patient is sufficient to scan a three-dimensional volume with lower radiation exposure. The three-dimensional volume can be described as field of view (FOV), its size depends on the device in use<sup>[1]</sup>.

Because of the increasing number of dental implants and the high capability of modern computers with respect to graphic card, main storage, hard drive capacity etc., the demand and need for three-dimensional radiographic diagnostics is increasing. The amendment to the German X-ray Ordinance (RöV) of July 1, 2002, responded to this development and introduced DVT as an accepted three-dimensional imaging technique in dentistry. Therefore, dentists with a certificate of specialist training are, apart from radiologists, the only ones who are allowed to implement a split-image procedure using DVT technology.

## Costs

While for a long time, only few, high end DVT devices were available on the market, about ten new

systems<sup>[2]</sup> were presented at the IDS 2007. They differed in the price-setting size of the captured volume, the sensor type (image intensifier system vs. flat-panel detector), the additional option to create dental panoramic tomographs (DPT) and the required space, among others.

When image intensifiers are used, a camera image is generated by x-ray quanta after conversion into electrons and intensification. Due to intensification, a lower dose is necessary, however, a stronger image noise becomes visible at higher resolutions. In flat-panel detectors, x-ray quanta generates an electron stream directly at the solid body detector. This requires a higher dose, but even in very high resolutions, low-noise images are obtained.

With a presentable volume of 5 cm diameter and 3.7 cm height, the digital radiography system KODAK 9000 3D (Carestream Health, Stuttgart, Germany) offers a relatively small field of view, but with a voxel size of 0.076 mm, the slice thickness is very low, providing a high resolution (separation effect between two structures, specification in line pair/mm). The voxel size describes the dimension of the volume, i.e. the volume of the pixels that the different data file sections are made up of. Dental panoramic tomographs (DPT) can be captured without manual intervention to change the sensor, thus, KODAK 9000 3D is a real dual-use device with minimal space requirements.

The costs for the most affordable DVT devices is meanwhile only little above the price level of a conventional DPT device with the possibility of transversal tomography making three-dimensional radiography affordable even for general dental offices. However, the question arises if small-volume DVT devices are economical and functionally suited for this group of users<sup>[2]</sup>.

## Indications

In general, the required background for the creation of a DVT image is the existence of a justifying indication according to § 23 of RöV, particularly because the radiation exposure in DVT can be four to ten times higher than in digital DPT.

The necessity of a justifying indicator means that an x-ray scan is allowed only if the medical benefit is higher than the radiation risk. In this context, an adequate procedure has to be selected for each specific case.

Although a definite list of indications is not yet available, there are some clues given in the three-step list of indications according to PD Dr. Dirk Schulze:

### 1. Dental questions

- Position of impacted teeth, relation to mandibular canal, maxillary sinus
- Cystic mass, inflammatory processes and relation to adjacent region
- Detection of small contaminants
- Morphology of the condylar process, pathological changes of the high-contrast structures
- Orthodontics
- Periodontics

At this point, conservative dentistry should be mentioned under reserve of verification.

### 2. Implantological questions

- Preimplantation diagnostics, data acquisition for navigation software
- Three-dimensional control of the implant after placement

### 3. Oral and maxillofacial surgery (OMS) questions

- Trauma
- Local cancer diagnosis
- Paranasal and maxillary sinus diagnostics
- Osteomyelitis
- Lip-jaw-palatine clefts

As a rule, the indications listed under point 3 should be subject to large-volume DVT devices and

thus treated in large practices specialized on oral and maxillofacial surgery or centers and clinics.

The DVT system KODAK 9000 3D is being used in my practice with a specialization in general dentistry, periodontics and implantology for more than a year now. In the following, several examples for indications according to point 1 and 2 will be given and the benefit of a DVT use for the dental practice is evaluated. The examples point out the possible quality for DVT images.

## Determination of the position of impacted teeth

The selection of DVT as an imaging method will be suitable if the conventional DPT image displays an unclear relative position to critical anatomical structures. With DVT, multiplanar reconstructions are possible in horizontal, sagittal and transversal directions so that a impacted tooth can be presented without any overlaps. Figure 1 shows a DPT without a clear distinction of the impacted tooth 38 from the inferior alveolar nerve. Figure 2 shows a DVT image

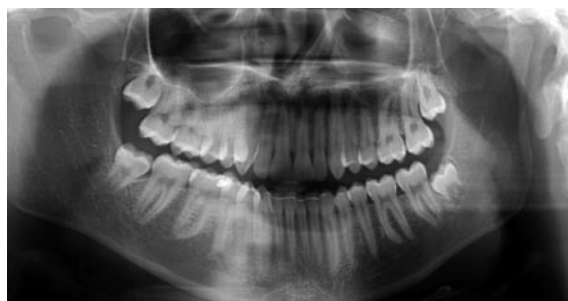

Fig. 1: DPT – no clear distinction of tooth 38 to the inferior alveolar nerve visible.




Fig. 2: A DVT image with KODAK 9000 3D.

captured with KODAK 9000 3D. With the integrated software offering intuitive use, the mandibular canal is marked in a simple way. With the function “angular cutting”, the relevant area is circumscribed three-dimensionally. On the DVT image, it becomes evident that the impacted tooth 38 is not in contact with the inferior alveolar nerve. The use of DVT for this indication is supported by many users<sup>[3, 4, 5]</sup>.

### Detection of small contaminants

Figure 3 shows the DPT with a pea-sized shadow in region 48 caused by a metal contaminant. The three-dimensional analysis of the region of interest (RoI) was done subsequently with a DVT in order to accurately determine the intraosseous position of the contaminant (Fig. 4).

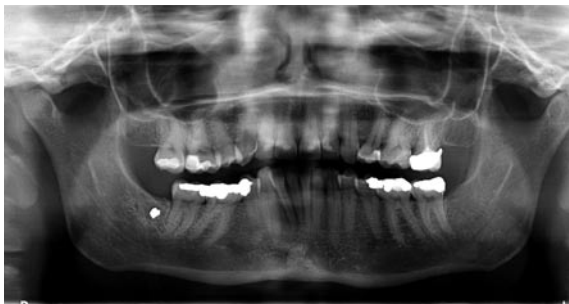

Fig. 3: DPT – shadows in region 48.

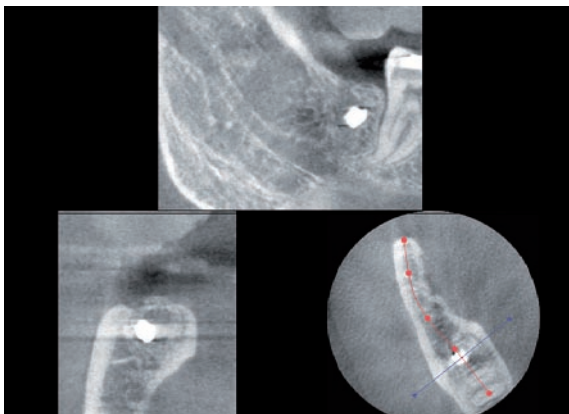


Fig. 4: DVT to determine the position of the contaminant exactly.

### Representation of the temporomandibular joints

The representation of hard tissue structures of the temporomandibular joints is possible with small-volume DVT devices as well. Figure 5 shows a three-

dimensional view of the left temporomandibular joint.




Fig. 5: 3D view of a left temporomandibular joint.

All over the globe, people are working on reconstruction algorithms for DVT images. Thus, it can be expected that the reconstruction of soft tissues, which is insufficient as yet, will be improved compared to CT in the future<sup>[1]</sup>. Currently, magnetic resonance tomography (MRT) is preferred as an imaging method in the context of temporomandibular joint diagnostics.

### Orthodontics

It can be assumed that three-dimensional radiography will establish itself increasingly in orthodontics. Here, the initial diagnosis is based on DPT. If retention, resorption, angulation or further pathologies are suspected, these can be diagnosed more precisely and safer above all with DVT than is possible with other imaging methods. Appropriate therapeutic measures are initiated in a more effective way. The representation of the broken teeth and the tooth germs is possible without overlap.

Figure 6 shows a supernumerary tooth 21 with dependent gemination. The DVT image reveals that the desired therapeutic separation of the teeth is impossible.

Especially from orthodontic practices, a strong tendency of increasing referrals for DVT is listed. With regard to DVT use in the context of pediatric questions, further scientific studies are currently being conducted.

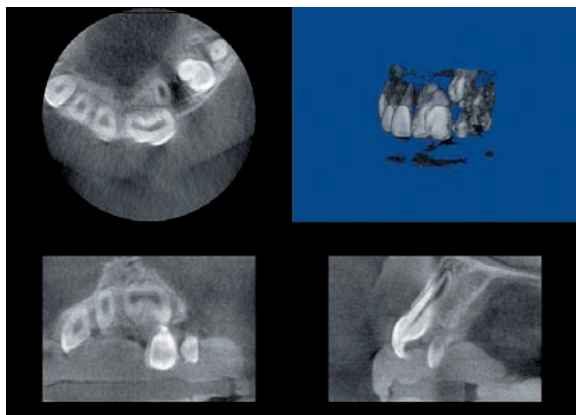


Fig. 6: Supernumerary tooth 21 with dependent gemination.

## Periodontics

The anatomy of the alveolar bone is not displayed in a differentiated way in DPT because of summation effects and overlaps. However, in DVT, the osseous anatomy is visualized. There are two different representations: one is surface-based – the surface of an object is displayed (surface shaded display = SSD), the other is volume-based (VRT = volume rendering technics) – a semitransparent representation of the volumetric content. KODAK 9000 3D features an appropriate software tool to reproduce the 3D setting. Like in a medical CT device, it is possible to determine a gray-scale value (threshold) and to edit this area with functions for brightness and contrast in order to blend bone and tooth structures. In this way, ossary defects, denudations, fenestrations, the degree of furcation involvement etc. can be visualized and qualified. The graphical representation determines the surgical approach. Figure 7, for example,




Fig. 7: Tooth 37 and horizontal bone resorption visible, furcation area identifiable from lingual view.

shows a tooth 37 and a horizontal bone resorption. The furcation area is visible from a lingual view.

## Endodontics

The employment of DVT is useful in endodontics to display additional canals, the canal positions, apical areas etc. Several authors support the use in endodontics<sup>[6,7]</sup>. The number of canals, e.g. a second mesio-buccal canal in a maxillary first molar, can be detected in this way just as an internal resorption etc.

Figure 8 reveals that the roots of tooth 26 enclose a recess of the maxillary sinus as well as that the mesio-buccal root has two canals and that tooth 27 has a second root canal without a filling. Root canal fillings, even after root tip resection, are displayed very well after fading out of the bone and hard tooth structure in the 3D view, only the root canal filling remaining

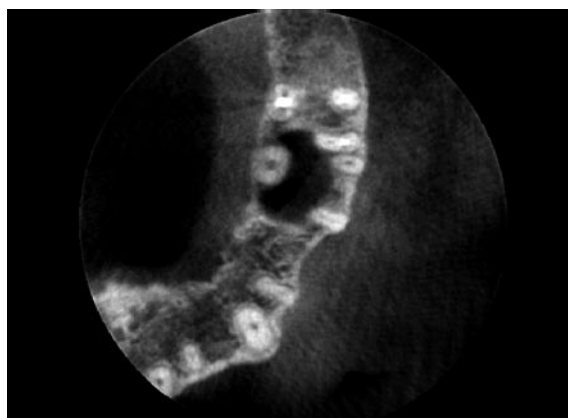


Fig. 8: Tooth roots 26 enclose recess of the maxillary sinus, mesio-buccal root has two canals, tooth 27 with non-filled second root canal.




Fig. 9: Tooth 26 with faded out bone and hard tooth structure.

visible. This is shown in figure 9 using the example of a tooth 26.

Technological optimization, e.g. with regard to an improved representation of small accessory canals due to reduction of the image noise (affects the differentiation of small image structures by quantum noise and system noise and electronic noise respectively / image quality is determined by noise, contrast and blur) is expected for the future.

### Caries diagnostics

I am skeptical with regard to the use of DVT for caries diagnostics. In the 3D view, carious lesions with a loss of hard substance are visible, however, bitewing radiographs are preferable for preventive caries diagnosis also for reasons of radiation hygiene.

### Preimplantation diagnostics

The greatest benefit of DVT is found for implant planning. In financial terms, it is only a minor expense factor for the patient related to the remaining costs of an implantation. Since the DVT image offers e.g. an accurate determination of the bone volume prior to implantation as well as the complexity of the surgery and, if need be, allows to predict the necessity of an augmentation beforehand, the dentist is able to make a precise estimate of the costs.

Due to detailed information about the bone dimensions, implantations have become faster, minimal invasive and more secure – the course of the intervention is predictable. Questions like “Is an internal sinus lift possible or will a one- or two-stage sinus floor elevation be necessary?” can be answered beforehand.

Also for the sinus floor elevation, information about the sinus anatomy is very useful. Figure 10 was consulted in the process of planning a sinus lift. It reveals that the anatomy of the recess of the maxillary sinus does not have any septa and the alveolar bone height is 4.3 mm in the area of the intended elevation. The arteria anonyma is visible in the medial area of the facial bone wall in the cross section (and can be spared or eliminated at an early stage!). Screening

of the metrical spread of the recess and its anatomy facilitates the preparation of the maxillary sinus epithelium. Figure 11 visualizes the condition after sinus lift. With this DVT image, the implant in region 26 was planned. The marked area indicates an extension of 16 mm.

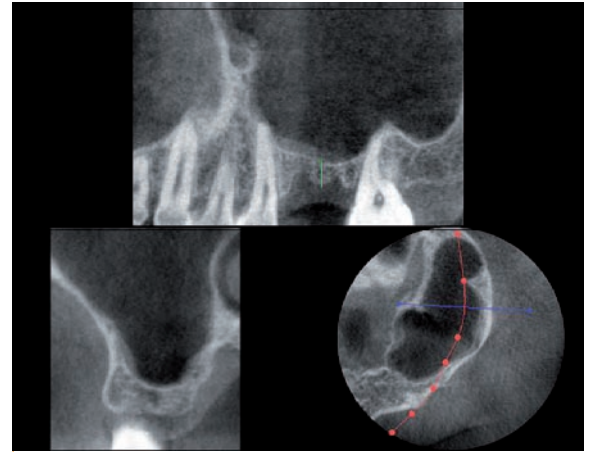


Fig. 10: DVT to plan a sinus lift.

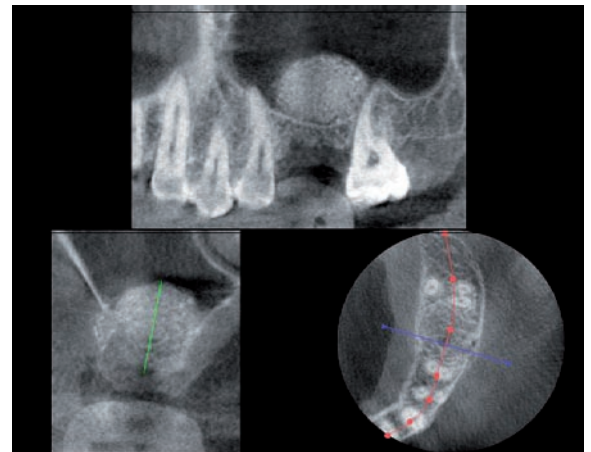


Fig. 11: Situation after sinus lift.

The objection of cost indicates that a sufficient pre-operative diagnosis is also possible with model analysis and a good DPT. It has to be pointed out, however, that due to overlap and summation effects, measuring errors of approximately 2 mm caused by projection can occur in DPT as opposed to inaccuracies in the range of 0.1 mm for DVT<sup>[8]</sup>. Figure 12 shows the consequences of measurement errors in this dimension: The implant in region 46 touches the mandibular canal. An iatrogenic damage was prevented only because the guiding principle in implantology of always maintaining a safety distance of 3 mm to the inferior alveolar nerve was respected.

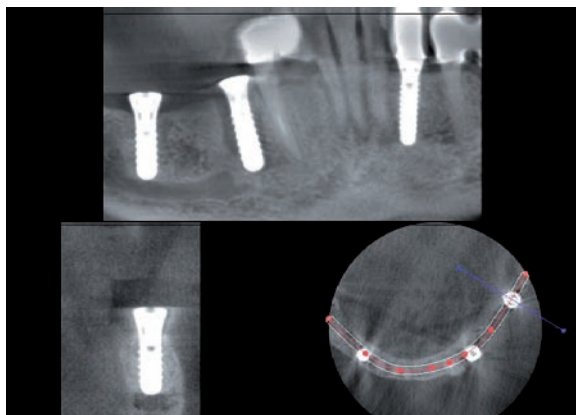


Fig. 12: Result of a measurement error due to projection – implant touches mandibular canal.

In region 44, which is also restored with an implant, periimplantitis is found. The figure shows the option of generating a pseudo-sagittal representation much like a DPT image from a curved representation with the software. Perpendicular to the panoramic reconstruction line, cross sections are created. The dentist is familiar with this kind of representation, which is particularly useful for implant position planning.

As a matter of course, data files of smaller volumes can be used for planning of implantological treatments with navigation programs as well, because the data output is possible in the international standard format DICOM 3.0. An individual implant library can be set up directly in the software of the radiography system.

### Three-dimensional implant monitoring

As a rule, monitoring after implantations is done with DPT or small-size image. In selected cases – e.g. after an augmentation or if fenestration is suspected – a DVT image is possible. It becomes evident that, opposed to the CT, almost no interfering metallic artefacts are caused by the implant. This can be traced back to different x-ray geometries.

Figure 13 shows the DVT control image of the situation in region 21 after an augmentation.

### Closing remarks

For quality control, the study group x-ray diagnostics in dental radiology recommends:

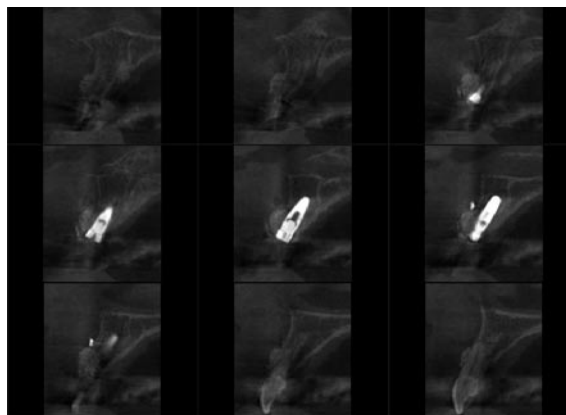


Fig. 13: DVT control image after augmentation in region 21.

- The volume includes the dentomaxillary viscerocranium.
- For smaller volumes, the highest possible spatial resolution should be chosen.
- The represented volume should be adapted to the clinical question.
- The radiation dose should be as low as possible and necessary.

In more than 90 % of the cases, a volume of 5 cm x 3.7 cm is absolutely sufficient. Among other things, the benefit of a smaller volume is a lower applied radiation dose. Since the justifying indication mandates the use of procedures with no or lower exposition to radiation if the benefit is comparable, strictly speaking, standard CTs are no longer allowed in the dentomaxillary area.

Moreover, the small volume requires less storage space (for KODAK 9000 3D, a slice thickness of 0.076 mm currently requires approx. 175 MB), reducing the costs for the provision of storage equipment and allowing a more efficient access. Since, for example, the radiograph of an eight-year-old child has to be stored for 20 years, the storage volume plays a relevant role despite increasing storage capacities. Due to the high amount of data on the whole, the installation of a practice network with high-quality components is important. Furthermore, professional support during installation is essential. The integration of the x-ray system software into a practice network and a connection to the existing practice software should be possible without problems. In addition, the use of larger volumes involves a complete interpretation of

the image, although dentists are usually not skilled for an assessment of the cranial areas displayed.

In search of an appropriate DVT device, the dentist should always pay attention to an easy use system that is easy to integrate into the practice workflow. In addition, the data should be easily exportable and an additional viewer should be available for other surgeries and users of the image free of cost. For an economical benefit, a focus of the practice on oral surgery is recommended. As explained above, I use DVT mainly within the scope of implantology. The economic efficiency can be calculated by taking into account the investment costs and the number of implantations. ■

## Bibliography

<sup>[1]</sup> **Schulze, R.:** Aktueller Stand der digitalen Röntgentechnik. In: ZM 6 (2006).

<sup>[2]</sup> **Koch, J.H.:** Die Zukunft ist dreidimensional – digitale Diagnostik verändert die Zahnheilkunde. In: ZM 8 (2007).

<sup>[3]</sup> **Becker, J.:** Operative Zahnentfernung und ihre rechtlichen Rahmenbedingungen. In: ZM 9 (2004, p. 62).

<sup>[4]</sup> **Vosshaus, J. et al.:** Genaue Lagebestimmung der unteren Achter prä-operationem. In: ZM 2 (2005).

<sup>[5]</sup> **Scherer, P.; Zöller, J.E. et al.:** Indikationen für die digitale Volumtomografie. In: ZM 6 (2008).

<sup>[6]</sup> **Tyndall, D.A., Rathore, S.:** Cone-beam CT diagnostic applications: caries, periodontal bone assessment, and endodontic applications. In: Dent Clin North Am 52 (2008), p. 825-841.

<sup>[7]</sup> **Patel, S.; Dawood, A.; Ford, T.P.; Whaites, E.:** The potential applications of cone beam computed tomography in the management of endodontic problems. In: Int endod J 40 (2007), p. 818-830.

<sup>[8]</sup> **Goch, I.:** Metrische Genauigkeit von Computertomografie, digitaler Volumtomografie und Orthopantomografie. In: DIGITAL\_DENTAL.NEWS 7 (2008), p. 6-12.

**Dr. Herbert Martin**  
Balingen, Germany



■ 1982 License to practice dentistry obtained at the Albert-Ludwigs-Universität Freiburg, Germany

■ 1983 Conferral of doctoral degree in dental medicine

■ Since 1986 working in own dental practice in Balingen, Germany

■ Specializations: general dentistry, implantology, periodontics

### Contact

**Dr.H.Martin@T-Online.de**