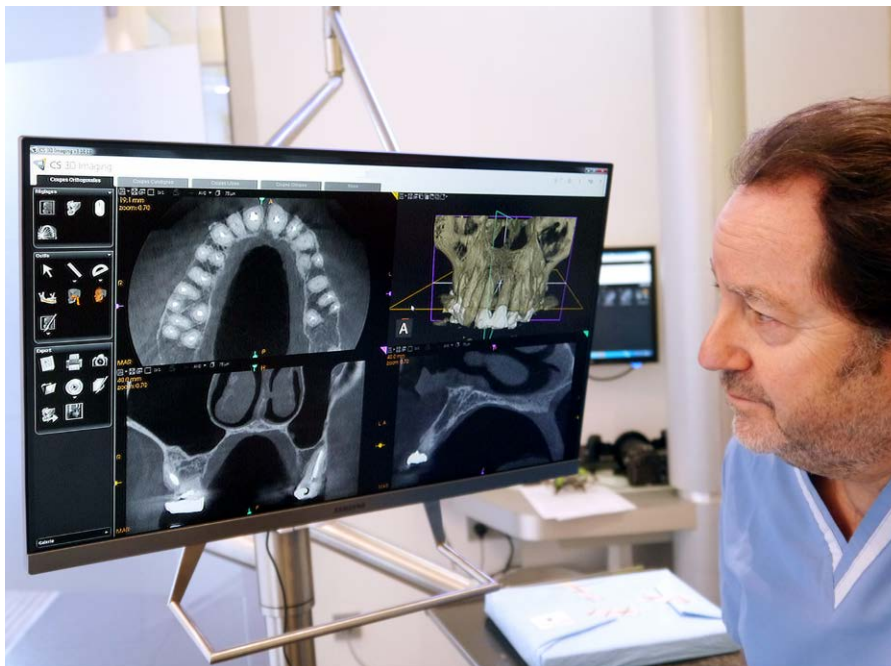

CLINICAL CASE

3D Imaging Software Functionality is Key to Workflow Efficiency

Dr. David Bensoussan



Challenge

Acquire higher quality CBCT images than existing system could produce

Solution

CS 9600

Benefits

- Intuitive, endodontic-specific functionality
- Improved ability to target a specific area
- High image quality
- Better artifact management
- Life-changing diagnostic capabilities

Intuitive, endodontic-specific functionality

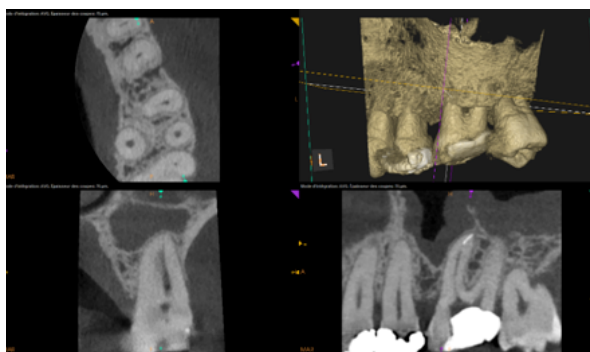
There's one thing that Dr. Bensoussan values more than CBCT imaging: the software that enables him to manipulate his 3D images. For the endodontist, it's crucial for diagnosis and treatment.

"I need to be able to navigate into the failed canal with my mouse and re-orient the plans permanently depending on the roots that we examine," he said. "It's not a static examination; it's a dynamic one."

If that imaging software is user friendly, even better. This is exactly what Dr. Bensoussan found with Carestream Dental's CS 3D Imaging software, which came with his new CBCT system, the CS 9600. "It's very intuitive, compared to all the other software I have worked with," said Dr. Bensoussan.

“When a patient comes in with a cone beam volume acquired somewhere else, I simply retrieve the DICOM files and read them. However, when I have to use another imaging software, it is very problematic. For endodontics, other software programs are practically unusable; they’re too complicated, and we cannot follow a canal or see the apical foramen as we would like. An image that I cannot explore confidently is of no use to me. I prefer to take another volume with the CS 9600.”

Dr. Bensoussan speculates that other imaging software may be better adapted to implantology and surgery rather than endodontics. “And on this aspect,” he said, “the 3D software from



“I need to be able to navigate into the failed canal with my mouse and re-orient the plans permanently depending on the roots that we examine. It’s not a static examination; it’s a dynamic one.”

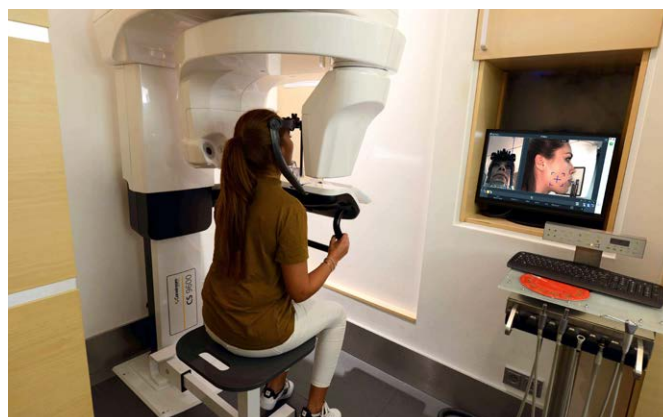Easy patient positioning

As for the imaging system itself, Dr. Bensoussan finds the CS 9600—like the imaging software—to be user friendly. “The CS 9600 is very easy to use,” he says. “The interface on the touch screen is quite intuitive. The seat immediately scored points because it greatly facilitates patient positioning.”

The CS 9600 assists the user in positioning a patient for imaging through color codes that light up when the user does not select the accessory appropriate for the exam to be performed. As a result, the positioning aids make it easier for Dr. Bensoussan and his staff to successfully capture an image on the first attempt. “And what constitutes undeniable time savings is working with excellent image quality,” he said.

Image quality that makes a real difference

For one case in particular, Dr. Bensoussan says that high-image quality was especially beneficial. The periapical X-ray did not reveal the root canal pathway during catheterization on a mandibular molar.



What Dr. Bensoussan saw in the CBCT image, however, matched exactly the patient's anatomy during the root canal filling. "Thanks to the CS 9600, I could see that there was a problem reaching the apex," said Dr. Bensoussan. "The CBCT scan demonstrated that the apical foramen was located on the distal aspect of the distal root, approximately 4 mm from the anatomical apex at a 90-degree angle. Moreover, a secondary apical foramen could be seen on the distal root at a superior position. This allowed us to follow the shape of the root canal's physiological pathway and avoid forcing the file out at the level of the radiographic apex."

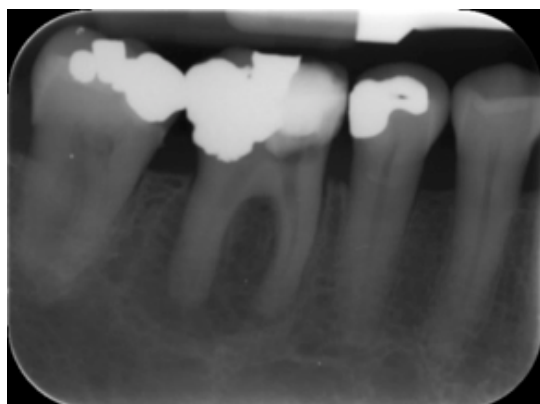


Fig 1: Periapical radiograph provided by referral doctor.

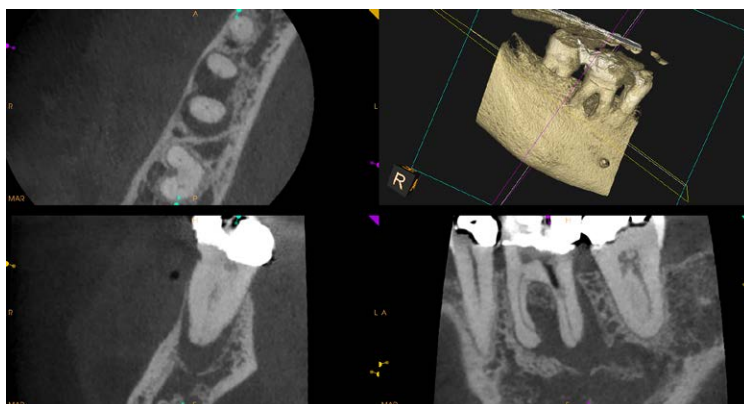
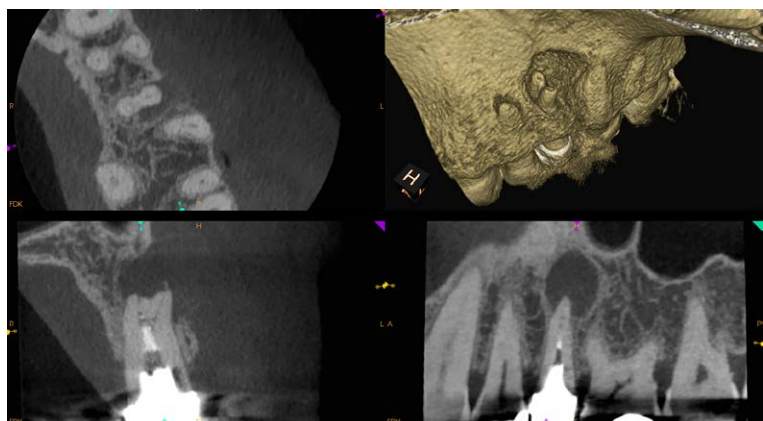


Fig 2: Three-dimensional view shows extent of the lesion and location of the apical foramen compared to the mesial apex.



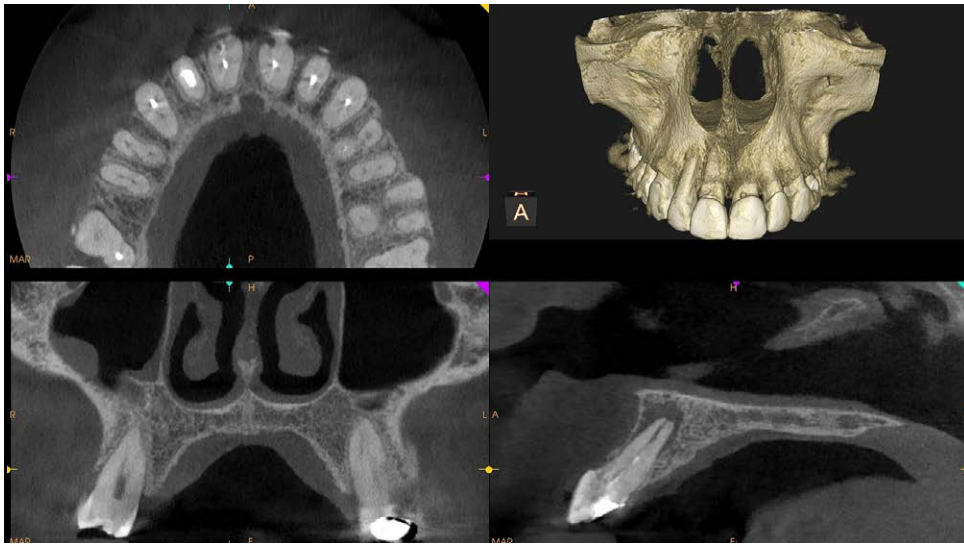Three-dimensional view – 75 micron resolution of an endodontically treated premolar demonstrates canal bifurcation at the apical third level and extent of the lesion causing interruption of the buccal cortical plate.

Dr. Bensoussan is not a newcomer to CBCT imaging. In fact, he was one of the first in endodontics to have one back in 2007. His CS 9600 replaces his previous system, which was also from Carestream Dental—and he's pleased with the advancements he sees in his new system. "Recently I had to open an image acquired with my old device, the CS 9000 3D. I was astonished by the clear improvement in the image quality. It is truly amazing."

Dr. Bensoussan appreciates the ability to use metal artifact reduction (MAR) when he evaluates an image. CS MAR is a patented software program that comes as an option on the CS 9600. "I use it systematically, and it is really helpful with posts and crowns," says Dr. Bensoussan.

Imaging versatility

The CS 9600 features 14 field-of-view options that range from 4 cm x 4 cm to 16 cm x 17 cm. Dr. Bensoussan values the imaging versatility that this brings. “What I really appreciate—compared to my previous machine—is being able to perform an examination of one sector but also a complete arch or even the whole mouth when it is necessary,” he said. “I can maintain the same precision at a maximum resolution of 75 microns.”



The ability to acquire a full arch CBCT scan at highest resolution (75 microns) is very valuable when multiple areas of interest are present or when a multidisciplinary treatment approach is conducted.

Life-changing diagnostic capabilities

When Dr. Bensoussan reflects on how the practice of endodontics impacts his patients, he feels confident that it is significantly beneficial. “We often detect diseases that patients have been dealing with for several years that are painful, and at times disabling. When we find the cause of the problem and manage to resolve it, it is life-changing for them.

And we have been able to do this for numerous patients.”

“I had a patient who, for more than two-and-a-half years, consulted all the specialties to no avail for a ‘small’ endodontic problem that no one was able to detect, and which resulted in diseases at the level of the sinus,” said Dr. Bensoussan. “When we finally managed to treat him, I can positively say that his life changed. There was something that had gone undetected, probably due to problems with reading and interpreting the slices. I emphasize once again: a file is all very well and good but being able to run it and manipulate it is better.”

About David C. Bensoussan, D.M.D., M.D.



David C. Bensoussan, D.M.D., M.D., a former Assistant Clinical Professor in Conservative Dentistry and Endodontics at the Dental School University of Paris, has been a Lecturer for the University of Implantology at the Hospital Saint Joseph in Paris since 1997.

A former President of Cercle Parisien d'Endodontologie Appliquée, and a Founding Member of the International Academy of Endodontics, Dr. Bensoussan lectures all over the world and has authored many papers and co-authored several scientific books.

Since 1983, Dr. Bensoussan has been in private practice, after receiving his Doctor in Dental Surgery, Strasbourg in 1981.

To learn more about the CS 9600, go to [carestreamdental.com](https://www.carestreamdental.com)