

# CBCT: A Valuable Tool in Endodontic Diagnosis and Treatment

by Dr. Sebastian Ferchero



## Dr. Sebastian Ferchero

Dr. Ferchero is a Doctor of Dental Surgery and holds a Diploma in Odontology from the Alfonso X El Sabio University (Madrid) in 2009 and an Inter-University Diploma in Endodontics from the University of Nice in 2018. Passionate about endodontics, he is continuously training.

In his spare time, he plays the trumpet. Occasionally he brings it to the practice to play between patients if he has cancellations - with a mute (if not he wouldn't keep his job!)

Radiographic analysis is an essential element in endodontic treatment, whether for diagnosis, treatment planning or evaluating results. Since the introduction of cone beam computed tomography (CBCT) in dentistry, its use has become increasingly common. It allows practitioners to view the structures of the oral cavity and its environment in three dimensions, unlike conventional 2D radiography. The two-dimensional nature of the latter results in a superimposition of anatomical structures and a certain degree of distortion. These disadvantages can be resolved thanks to the 3D images captured by a cone beam CT system.

## Patient Situation

A 45-year-old patient came to our office in Nice for an opinion on tooth #16. Her dentist referred her to us for specialized care to improve upon previous endodontic treatment. The anamnesis revealed a history of repeated abscesses.

## Diagnosis

The day of the consultation the tooth was asymptomatic. A clinical exam was performed and radiographs captured with the CS 7600 imaging plate system (Fig. 1) allowed us to diagnose chronic apical periodontitis.

To establish a precise treatment plan, a localised CBCT scan with the CS 9600 was performed. The choice of a small field is usually preferred by endodontists, due to the small volume to be interpreted.

This exam allowed for a three-dimensional analysis of the root and canal anatomy and provided a detailed image of the extension and location of the lesion (Fig. 2).

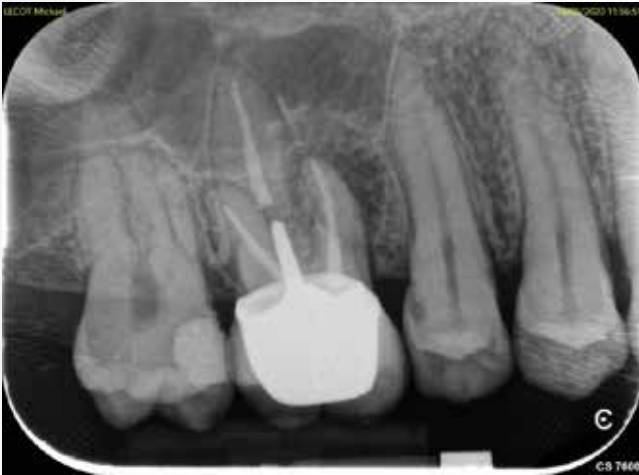

Figure 1: The retroalveolar image captured with the CS 7600 provides an essential overview for evaluating the quality of the prosthetic reconstruction, the periodontium and the mechanical prognosis of the tooth

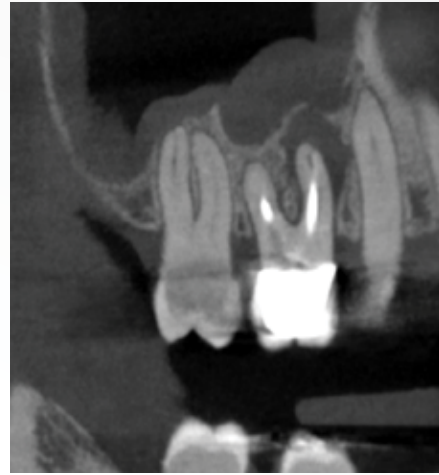


Figure 2: The CBCT image gives a more precise image of the extension and location of the lesion

According to a study by Dr. Paula-Silva,<sup>1</sup> there is a false negative rate of 21% when apical periodontitis is identified in the retroalveolar, but the rate is only 9% when CBCT is used. He therefore concludes that CBCT is more sensitive in diagnosing apical periodontitis compared to conventional radiography. According to another study published by Estrela et al,<sup>2</sup> cone beam CT exams also allow for faster and more precise detection of periapical disease.

In the present case, a periradicular lesion of the distal root, not visible in the retroalveolar image, could be highlighted thanks to 3D imaging (Fig. 3). The coronal and axial sections also showed the presence of an untreated canal in the mesial root. The detail of the CBCT image even made it possible to follow the path of this canal, carefully observing each section (Figs. 3 and 4)

Moreover, it was observed that the obturation of the MV canal was not centered in the root in the vestibulo-palatal direction, leaving a space where the MV II canal was located. The origin of an endodontic infection focus is normally centered in the lesion. The coronal section revealed that the apical image was not related to the previously treated mesio-vestibular canal.

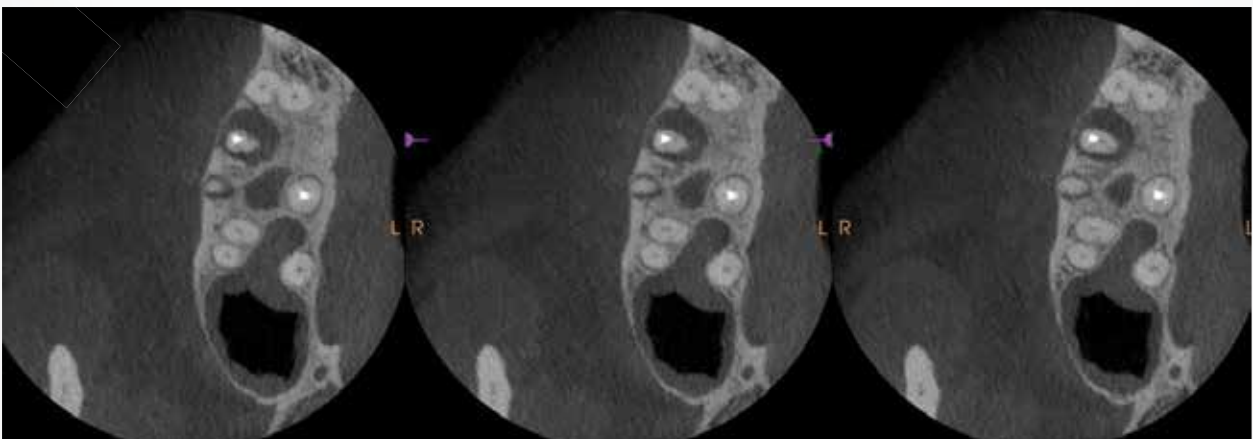


Figure 3: The axial and coronal sections show that the MV II canal foramen is located mesially and palatally to the MB canal. An infectious focus next to the distal root was observed.

These sections are specific to cone beam CT imaging and allow us to highlight images that are not visible in conventional radiography.<sup>3</sup> They are therefore valuable to the endodontist.

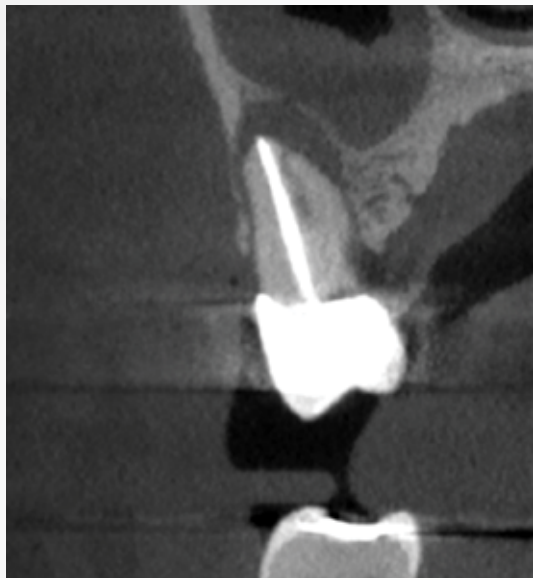


Figure 4: The CS 9600 has a high definition sensor (voxel size 0.75 $\mu$ m) so a volume of 5 x 5 cm was chosen to carry out the examination.

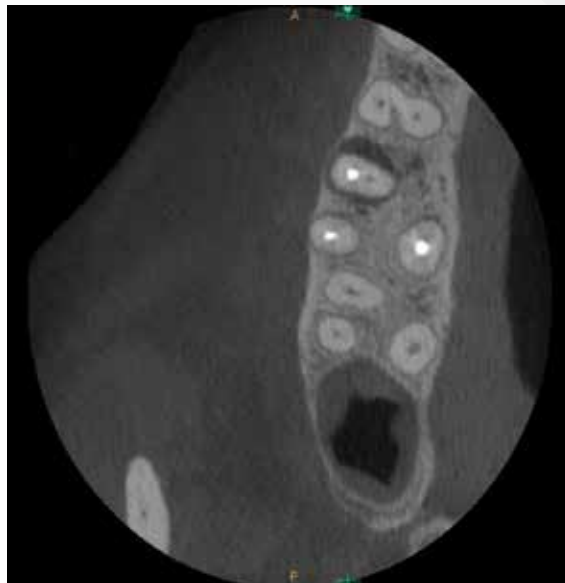

Figure 5: The MV II channel is visible on both sections

These findings are not trivial. According to a classic study of endodontic literature, non-surgical retreatment of a tooth having a correct filling in terms of extension and density (which was the case here in the retroalveolar view) offers one of the worst prognoses in endodontics due to the possibility of a root crack/vertical fracture or the presence of a bacterial flora that is very difficult to eliminate.<sup>4</sup> The untreated MV II canal was interpreted as a potential source of failure of the previous endodontic treatment.

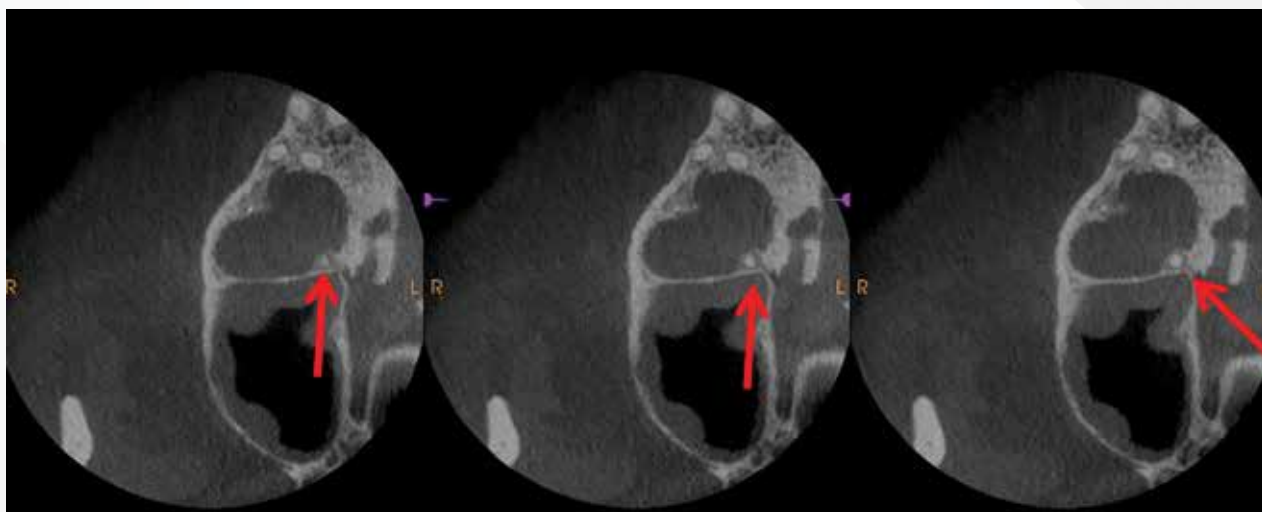
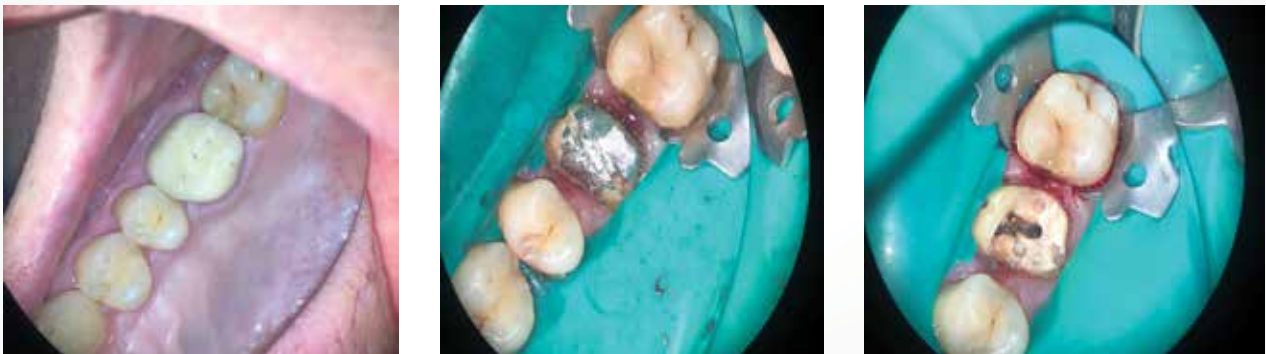

Figure 6: Less obvious is the diagnosis of the palatal root. A very discreet radiolucent zone seemed to be present around the apex in the axial section, but is there really a lesion?

Due to the sensitivity of CBCT, there is also a risk of false positives;<sup>5</sup> therefore, it could not be confirmed if the root was pathological—unlike the mesial and distal roots—where the presence of a well-demarcated radiolucent zone had been identified. Given these results, endodontic retreatment by orthograde approach was proposed to the patient.

### Treatment

After local anesthesia with a cartridge of articaine 4%, 1:200000, the prosthetic crown and the abutment were deposited using transmetal burs and ultrasonic inserts. To do this, the dam was placed in a split dam to separate the soft tissues and to improve visibility; the removal was then done under a microscope. The surgical field prevents metal particles released during the procedure from falling into the patient's mouth. (Figs. 7, 8, and 9)



Figures: 7-9: Even though the removal was carried out under a microscope, traces of the transmetal burs are visible in the dentin.

A pre-endodontic build-up was performed using a light-curing composite. In order to improve sealing, strips of PTFE (teflon®) were compacted before bonding between the tooth and the gum, to later be removed during polishing.

A new rubber dam was placed on the affected tooth to improve isolation (Fig. 10).

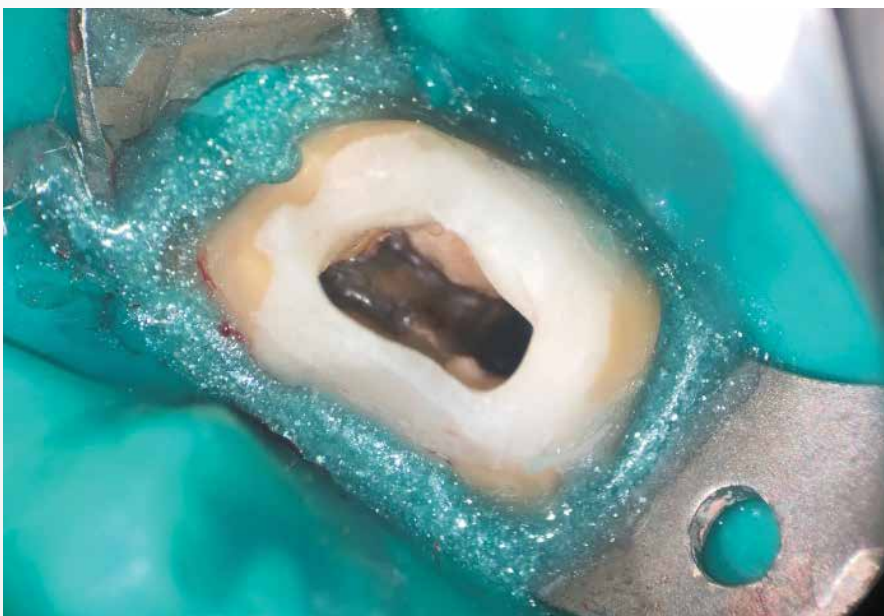

Figure 10:  
The tooth was isolated thanks to the pre-endodontic reconstitution and the liquid dam

The pulp chamber was arranged and the MV II canal highlighted using burs mounted on a Long Neck contra-angle.

The catheterization of the MV II canal was performed using a C plus #10 file introduced passively into the entry hole, though it was difficult for the file to progress beyond the first few millimetres. Therefore, an SX gold file in continuous rotation (250rpm) was used to remove the Schilder's triangle, allowing for a straighter and easier access route for the handheld instruments (Fig. 11).

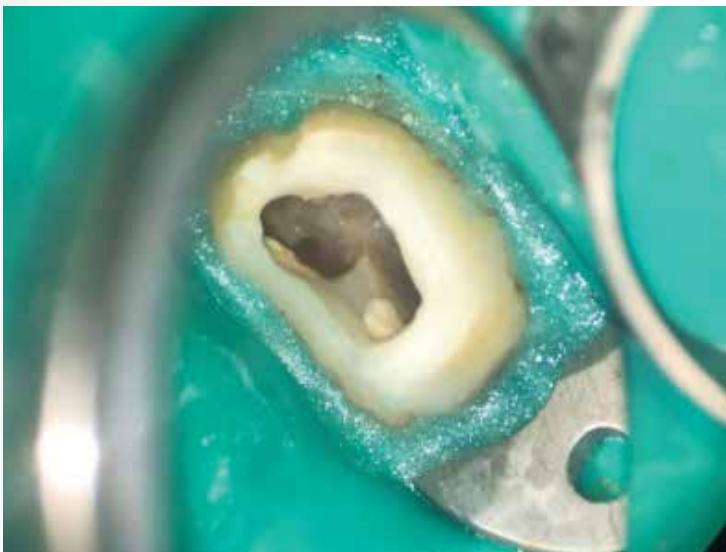

Figure 11:  
The orifice of MV II canal was located and enlarged (this is an occlusal view)

The removal of the canal blockage and the shaping of the MV II canal were performed using Gates n° III drills in the coronal third of the canals, then using FANTA blue S one files with abundant 2.5% Na OCl irrigation. Thanks to the apex locator integrated in the VDW gold motor, the working length was easily reached and the apexes are gauged and widened up to #35 gauge.

When the instrumentation was finished, the final irrigation was performed with the Endoactivator to activate the irrigation solution; namely, two cycles of 2.5% sodium hypochlorite for one minute per canal, alternating with irrigation with EDTA 17% for one minute per channel.

The canals are dried with paper cones, the gutta percha cones are calibrated and the obturation by vertical compaction was carried out using the Elements Free system with a resin-based sealing cement (AH plus). The final radiography captured with the CS 7600 confirmed the initial diagnosis: The presence of two independent foramens in the mesial root (Fig. 12).

An analgesic treatment (500mg of Paracetamol three times a day for three days) was prescribed to the patient to manage postoperative pain. Definitive corono-radicular reconstruction, as well as a temporary crown in order to ensure coronal sealing and to keep the tooth functional, was recommended to the patient as soon as possible.

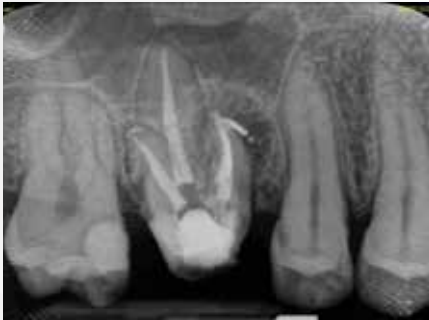

Figure 12: Postoperative radiography



Figure 13: Closed MV and MV II canal

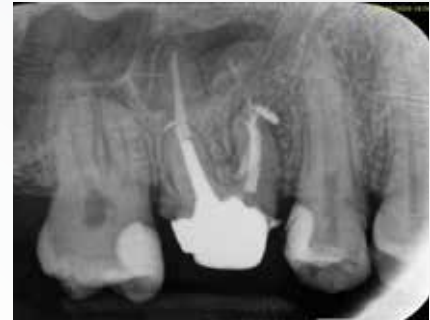

Figure 14: Postoperative at four months

A follow-up appointment was scheduled for six months later to check the periradicular healing. No symptomatology was described by the patient since the end of the treatment. Nevertheless, an overflow of obturation cement was still present in the mesial root, and the bone healing did not seem to be completely accomplished.

Therefore, a new CBCT exam was performed, this time with a small ultra-low dose field in order to reduce the dose delivered to the patient as much as possible. This type of examination is rarely chosen for the analysis of a complex root canal anatomy or for the detection of a root fracture, but it was useful in the clinical situation described (Figs. 15, 16, 17).

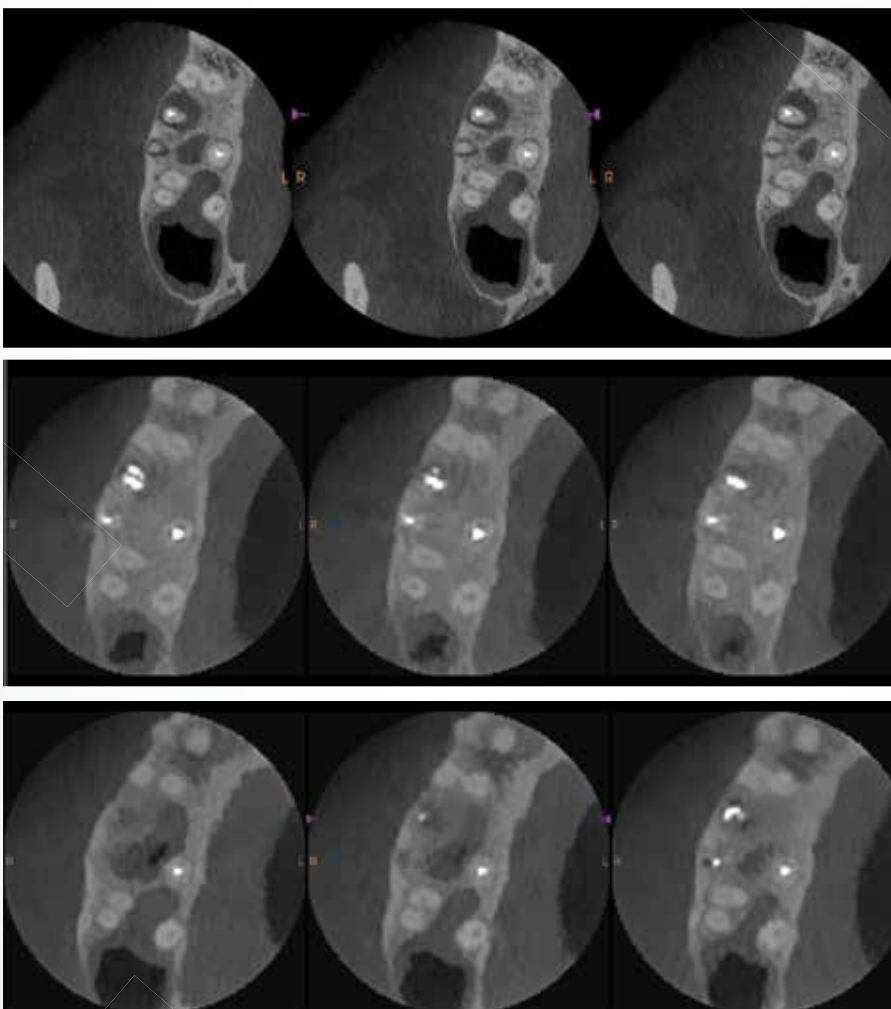


Figure 15: High-definition preoperative axial sections (above) and ultra-low dose postoperative axial sections. (below)

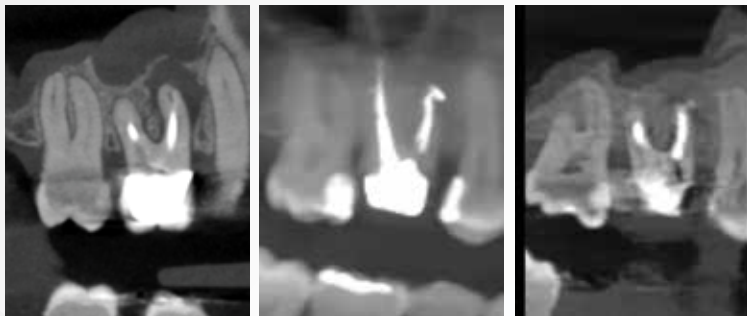


Figure 16: Preoperative (left) and postoperative (right) sagittal sections

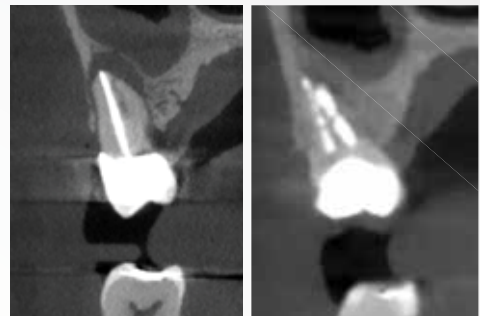


Figure 17: Preoperative (left) and postoperative (right) coronal sections

The DAP (dose area product) displayed for low-dose CBCT for this examination was  $32\text{mGy}/\text{cm}^2$ . By way of comparison, the dose delivered by the same device for a dental panoramic on a patient of similar height and weight is approximately  $150\text{ mGy}/\text{cm}^2$ ; for a maxillary CBCT (volume of  $12 \times 8\text{ cm}$ ) at standard resolution, it is approximately  $500\text{ mGy}/\text{cm}^2$ .

These elements give an idea of the dose received by the patient. The setting time and the display time are also less important in comparison with a high-definition examination. The definition of the image is, however, slightly compromised.

Following the analysis of these images, it was determined the lesion was still healing, and the green light was given for definitive prosthetic reconstruction. A new check-up appointment was scheduled for one year.

## Conclusion

CBCT is an essential tool in modern endodontics. It cannot replace conventional radiographic images, but it complements them. In this sense, the 3D images captured with the CS 9600 gave us a better understanding of the pathology; gave us more confidence in our treatment plan; and let us communicate better with the patient.<sup>7</sup> All of this was done with a benefit-risk ratio clearly in favor of the patient, in a relatively short time, and all within the same office.

1. De Paula-Silva FWG, Wu M-K, Leonardo MR, et al. Accuracy of periapical radiography and cone-beam computed tomography scans in diagnosing apical periodontitis using histopathological findings as a gold standard. *J Endod* 2009;35: 1009–12.
2. Estrela C, Bueno MR, Leles CR, et al. Accuracy of cone beam computed tomography and panoramic and periapical radiography for detection of apical periodontitis. *J Endod* 2008;34:273–9.
3. Matherne R, Angelopoulos C, Kulild J, et al. Use of cone-beam computed tomography to identify root canal systems in vitro. *J Endod* 2008;34:87–9.
4. Treatment Outcome in Endodontics: The Toronto Study—Phases 3 and 4: Orthograde Retreatment Cristian de Chevigny, DMD, MSc,\* Thuan T. Dao, DMD, MSc, PhD,†Bettina R. Basrani, DDS, PhD,\* Vincent Marquis, DMD, MSc,\* Mahsa Farzaneh, DDS, MSc,\* Sarah Abitbol, DDS, MSc,\* and Shimon Friedman, DMD *J. Endod* 2008
5. Diagnostic accuracy of cone beam computed tomography used for assessment of apical periodontitis: an ex vivo histopathological study on human cadavers C. Kruse , R. Spin-Neto, D. C. Evar Kraft, M. Væth & L.-L. Kirkevang. *IEJ* 2019
6. Endodontic outcome predictors identified with periapical radiographs and cone beam computed tomography scans. Liang YH, LiG, Wesselink PR, Wu Mk . *J. Endod* 2011 ;37 : 326-331
7. Fayad MI, Nair M, Levin MD, et al. AAE and AAOMR joint position statement: use of cone beam computed tomography in endodontics 2015 update. *Oral Surg Oral Med Oral Pathol Oral Radiol Endod* 2015;120:508–12