MULTIPLE UNIT CASE USING SMOP GUIDED SURGERY PLANNING WITH THOMMEN MEDICAL IMPLANT SYSTEM

CS 3600, CS 8100 3D AND PROSTHETIC-DRIVING IMPLANT PLANNING MODULE

A patient was referred to Dr. Mathieu Rousset following the fracture of the root of tooth 12, which had a bridge. The patient wanted a fixed solution.

A digital impression was taken with the CS 3600 intraoral scanner to capture the soft tissue and adjacent teeth.

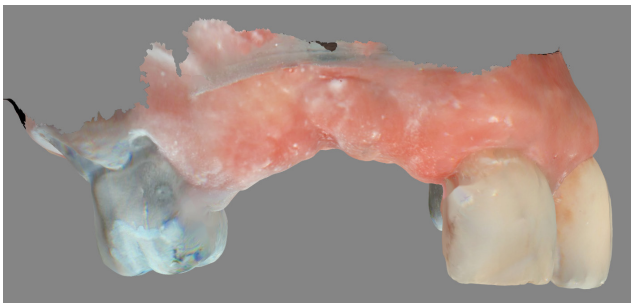

A CBCT volume was captured with the CS 8100 3D.

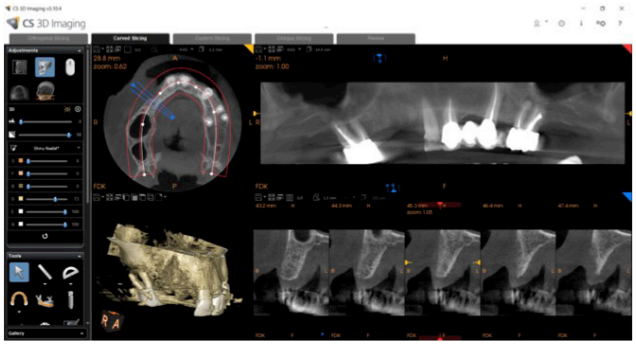

Mathieu Rousset

Doctor of Dental Surgery

Certificate of Advanced Study of Biomaterials used in Dentistry

Certificate of Higher Education in Surgical Dentistry

Certificate of University Study of Maxillo-Facial Imaging

Certificate of University Study in Periodontology

University degree in CAD/CAM

Inter-European University Diploma in Implantology

OTHER POSITIONS:
EMS speaker

Founder and director of AMPIO (Training Association of Periodontology and Implantology).

Key opinion leader with THOMMEN

Exclusive exercise in periodontology and implantology

PUBLICATIONS:
« Mise en charge immédiate : A propos d'un cas clinique».

Stratégie Prothétique : juin 2006 . vol 6, n° 3

Hand in hand : Practice meets industry (European journal for dental implantologist 2/2018)

L'empreinte optique en implantologie (Dentoscope n°197 26/09/2018)

WEBSITES:
Mathieu-Rousset-Chirurgien-Dentiste.fr

Ampioformation.com

The CBCT volume was automatically merged with the soft tissues using the Prosthetic-Driven Implant Planning module in the CS 3D Imaging software.

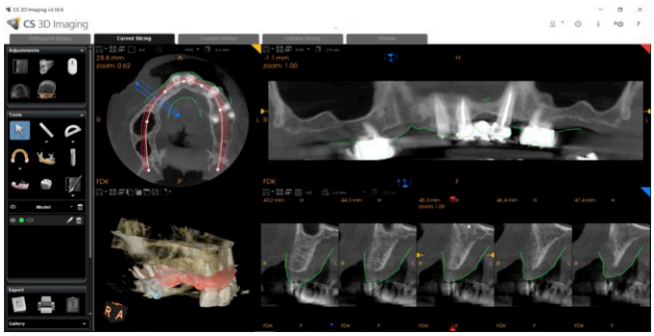

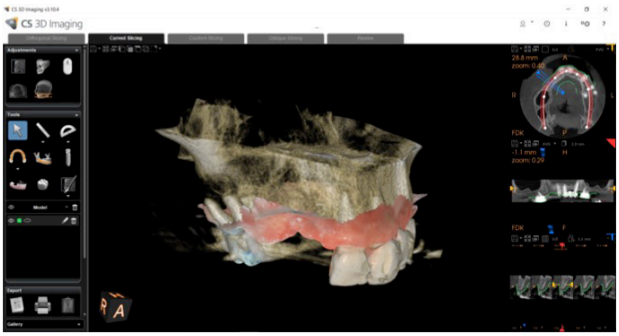

A virtual wax up has been created using the CS 3D Imaging Software Tooth Library to simulate the final prosthetic outcome and plan the implant.

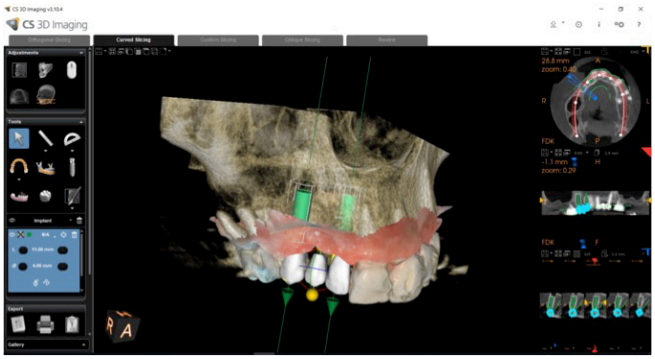

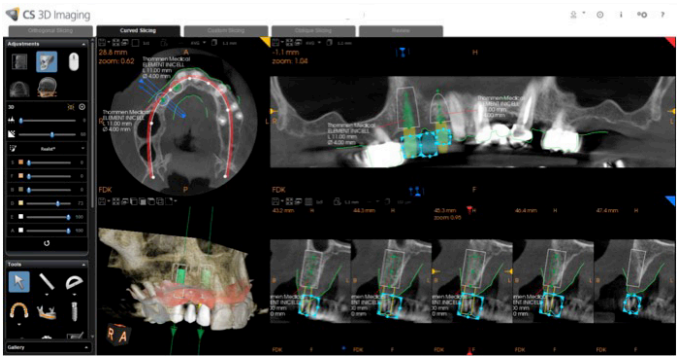

Planning the implant using the prosthetic-driven implant planning module within CS 3D Imaging software.

In a single click, the prosthetic-driven planning analysis was transferred to the SMOP guided surgery software to begin the guided surgery design phase. The SMOP software uses the analysis to propose compatible guided surgery sleeves.

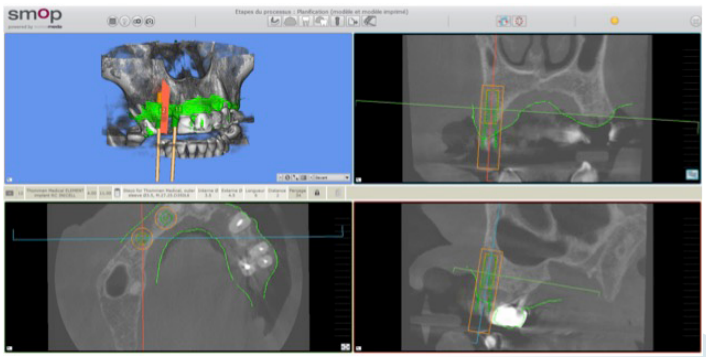

Using the SMOP design module, the surgical guide was designed, which involved adding several clips to the remaining teeth and the buccal and lingual side of the jaw to optimize the fit of the surgical guide. Once the design was complete, the software automatically generated an STL of the guide design. The surgical guide was then printed in the dental practice using the Formlabs Form 2 3D printer.

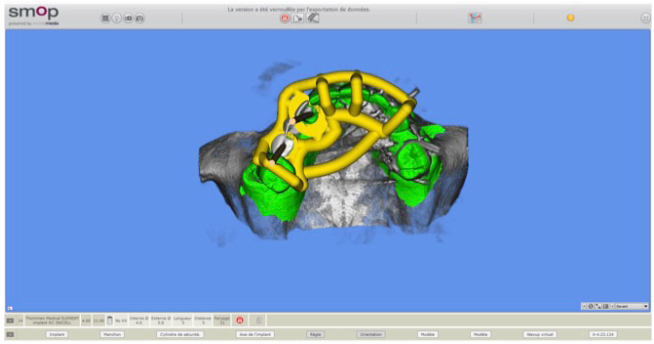

Thommen Medical guided surgery kit, which contains drills that accommodate the guided sleeve length.

The surgical guide was positioned and anchored on the patient's remaining teeth.

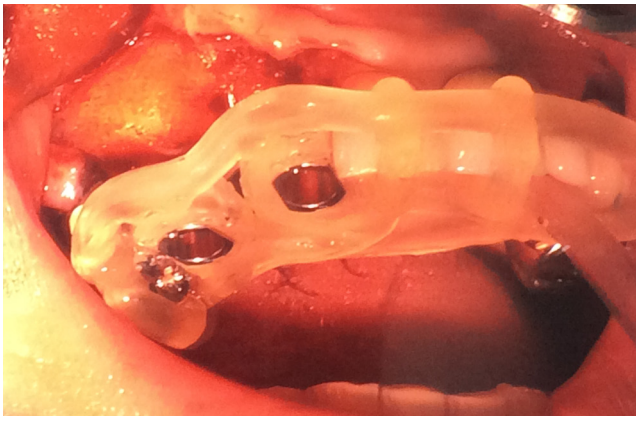

Adapted guided drilling sequences were performed using the Thommen Medical guided surgical kit.

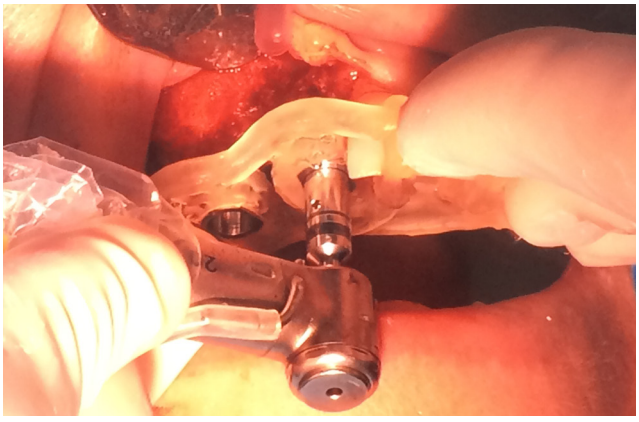

Once the implants were placed, Thommen Medical scanbodies were added in preparation for the digital impression which will record the implant positioning.

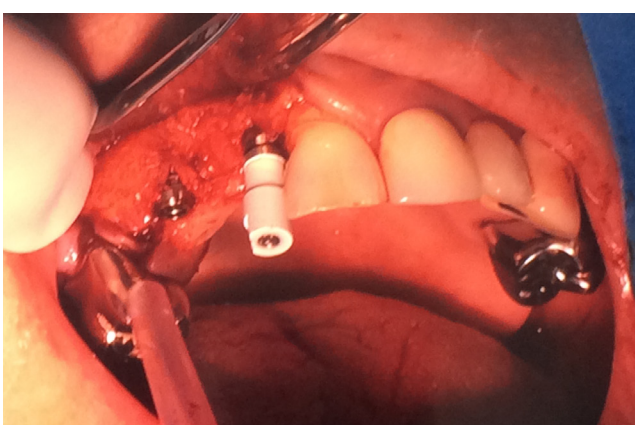

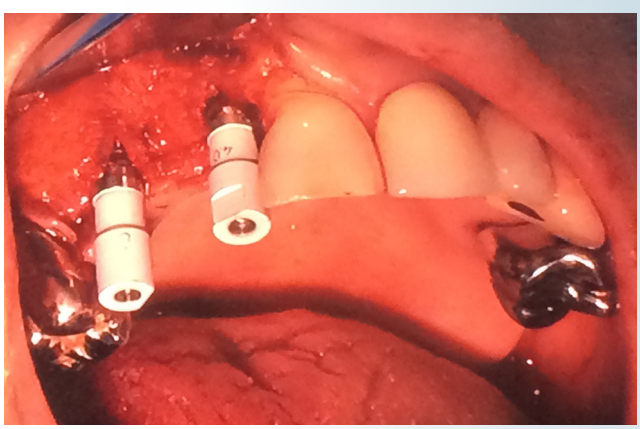

Scanbodies were screwed in and bone regeneration was performed. Instead of a traditional impression, a digital impression is taken, which eliminates the risk of:

- Contamination of the site
- Stitches being torn out
- Silicone passing between the edges of the site

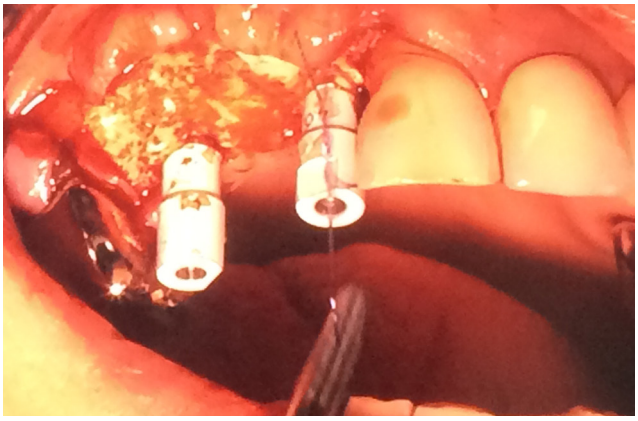

Thommen Medical REGEDENT graft material placement.

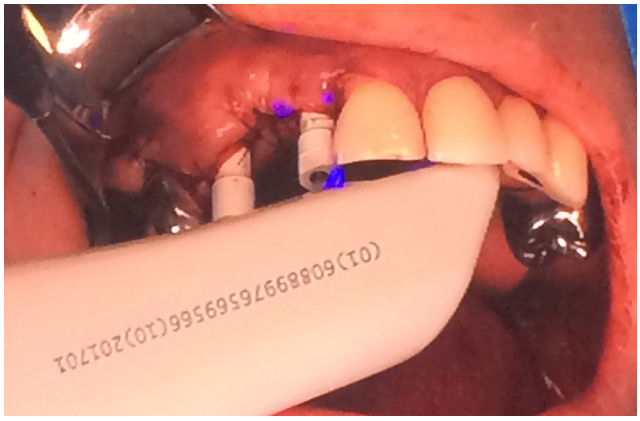

Scanning with the CS 3600 intraoral scanner to create the digital impression.

The temporary bridge was designed by Mobifix Laboratory using dental wings software, and it was manufactured in a ceramic-filled resin wafer. Variotemp abutments were glued into the prosthesis, which was placed 24 hours post-surgery.

Final outcome.

© 2018 Carestream Dental LLC. 17993 DE Software CSY 1018