CS 3600: IMMEDIATE EXTRACTION AND IMPLANTATION OF LATERAL INCISOR IN COMBINATION WITH THE CS 3600 BY CARESTREAM DENTAL, MGUIDE BY MIS-IMPLANTS, AND EXOCAD SOFTWARE

Dr. Mithridade Davarpanah

A middle-aged male patient presented with a long-term fracture to his lateral right maxillary incisor, and was seeking a permanent restoration. The crown of the tooth had been stabilized years ago with a temporary mesh bonding, which had deteriorated over time. Diagnostic records were taken, including vestibular and lingual views of the maxillary arch showing deterioration of the temporary stabilization, and a PA radiograph of the lateral incisor clearly showing the high root fracture.

Initial situation on left, post-whitening shown on right

A complete digital approach was taken to planning the treatment for this case. An optical scan of the patient's dentition was obtained using the CS 3600 by Carestream Dental, and CBCT images were acquired.

An initial ISQ reading of over 68 was obtained using the Ostell machine. The customized preformed milled healing abutment was placed, which allowed for the contouring of the gingival tissues at the time of implant placement.

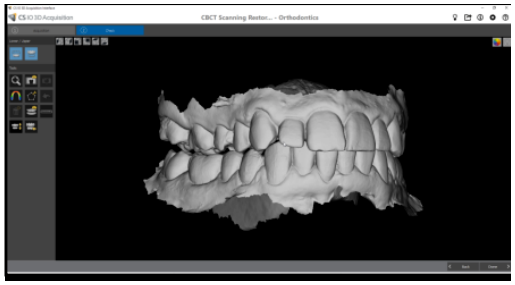

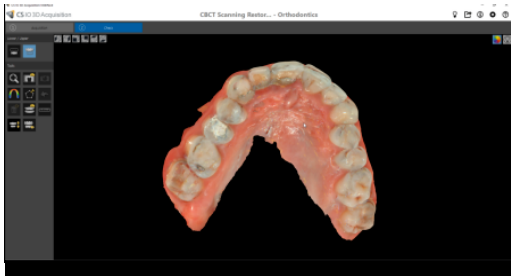

Patient was scanned with CS 3600

Next, the CS 3600 digital impression and CBCT datasets were imported into MIS MSoft CAD software for planning of the implant placement, size and position. Due to the narrowness of the site, an MIS V3 Ø3.3 x 16 mm implant was selected.

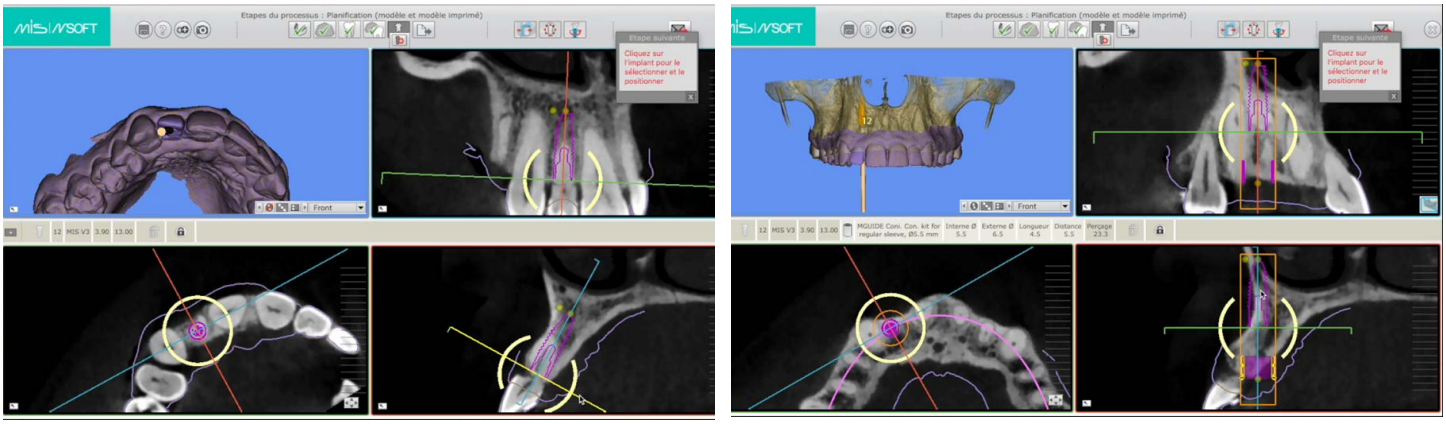

CBCT + CS 3600 Digital Impression imported into MIS MSOFT Planning software

The surgical guide was then designed based on the position and size of the implant and was sent to be manufactured.

The printed surgical guide template and resin support were manufactured

Next, the crown of the lateral incisor was extracted and the MGUIDE surgical guide template was placed to verify that seating and stability were correct.

Crown of the lateral incisor was extracted

The MGUIDE surgical guide template was placed to verify that seating and stability were correct.

Next, the appropriate MGUIDE Conical Connection pilot drill kit was selected based on the implant and sleeve size for the guide. The pilot drills were selected from the MGUIDE pilot kit in the appropriate drilling sequence, beginning with the starter drill, and then proceeding with the guided pilot and conical drills.

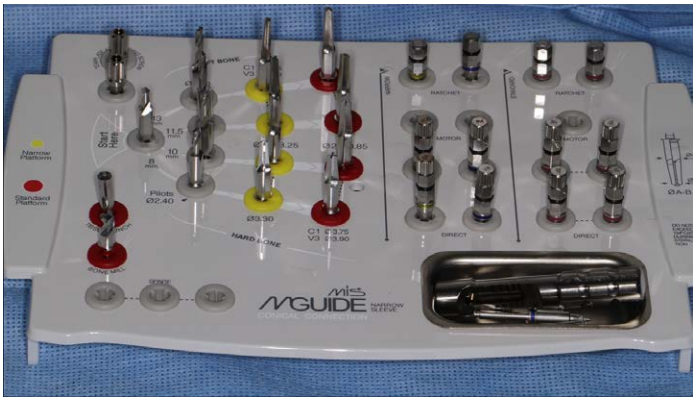

MGUIDE pilot drill kit

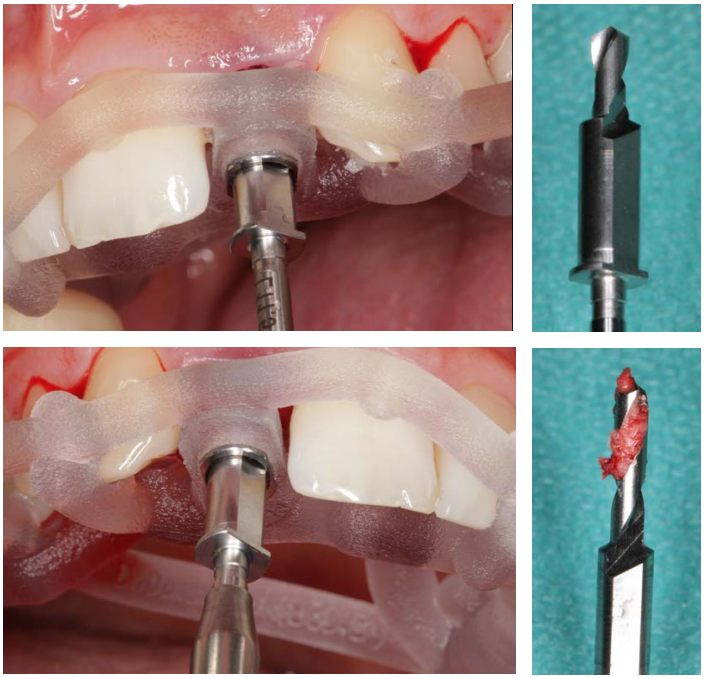

Starter drill top, guided pilot drill bottom

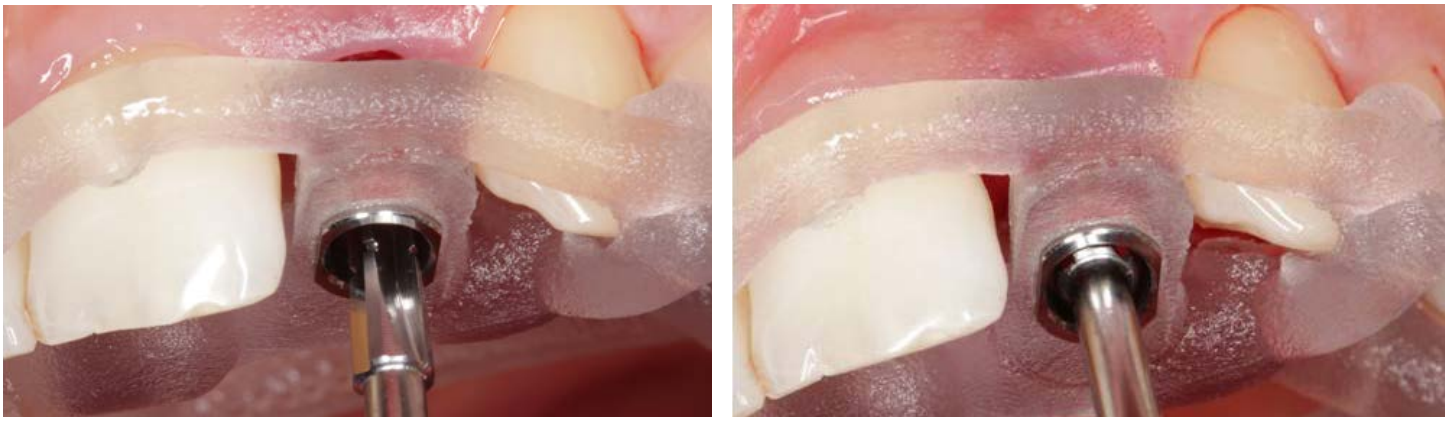

Conical drill

Once the drilling sequence was complete, the implant was inserted using a ratchet tool, and the placement verfied by seating the guide.

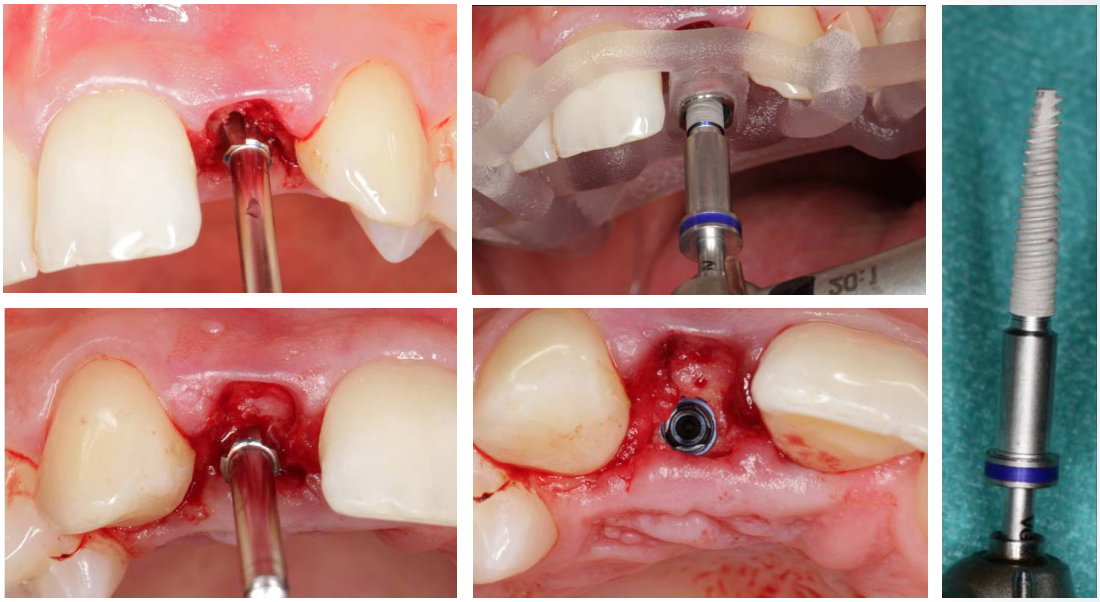

Implant placement

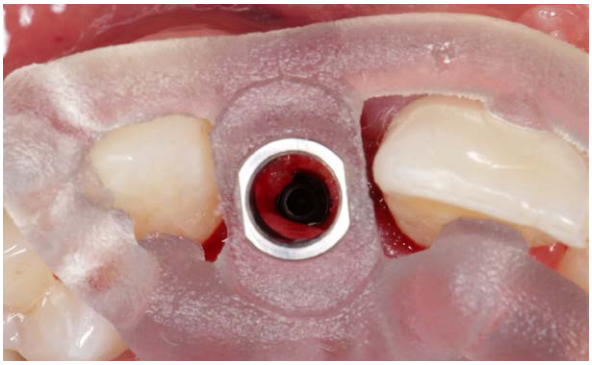

Placement verfication with guide template

The abutment was placed and a soft tissue graft was performed. The graft tissue was harvested from the posterior region of the patient's palate. A postoperative radiograph was taken to verify the implant placement with the healing abutment.

Abutment placement

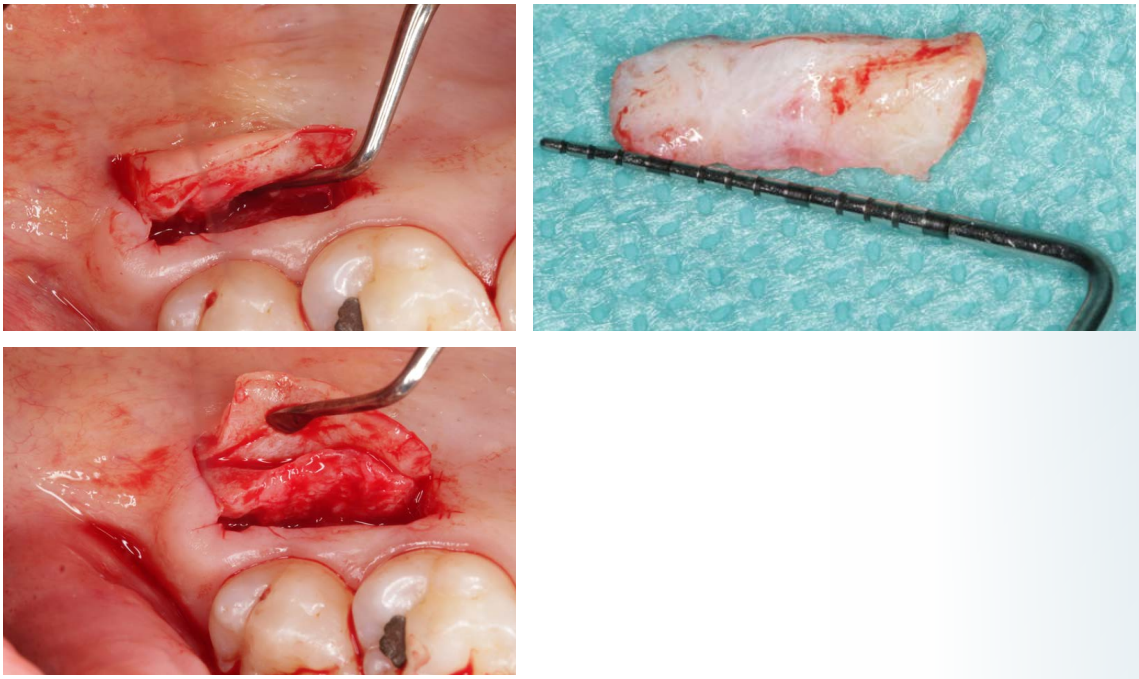

Harvesting of graft tissue



Healing abutment with graft placed

The appropriate scanbody was selected and placed, and an X-ray was taken to verify that the scanbody was seated correctly. The patient was re-scanned with the CS 3600 to obtain a digital impression to be used for restoration planning. As a time-saving measure, the previously scanned dataset was used and only the lateral incisor with the scanbody was re-scanned.

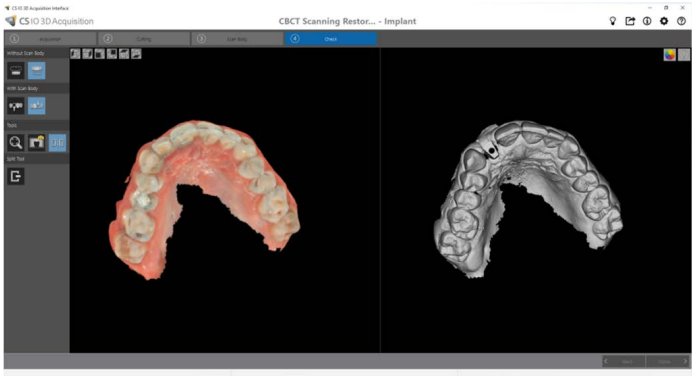

Optical impression of scanbody

The STL file was imported into Exocad software to plan the restoration design. The correct 3 mm Ti-base implant and scanbody were selected in the software. The new restorative crown was designed in Exocad software based on the placement of the patient's implant

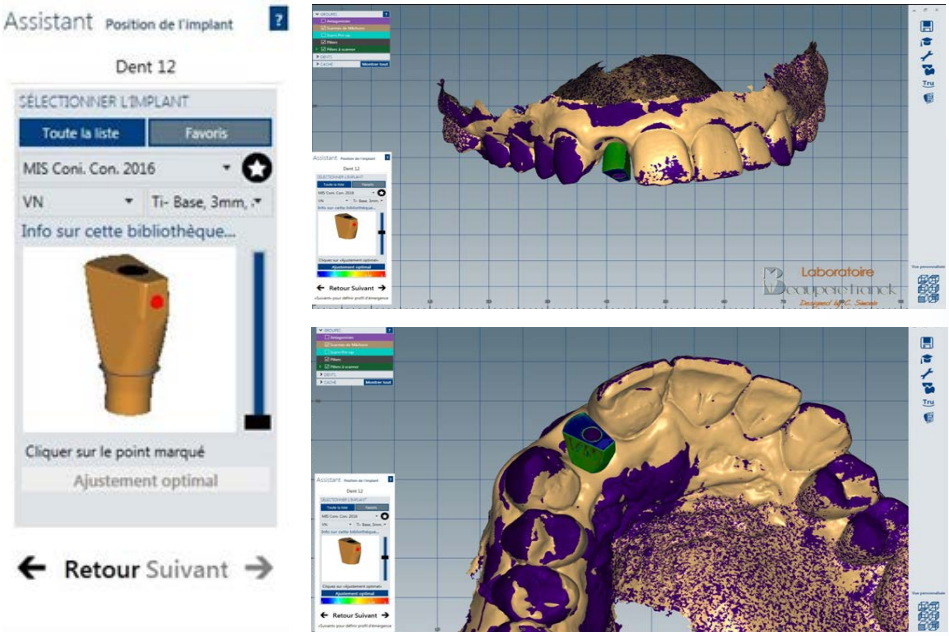

Restorative planning in Exocad software

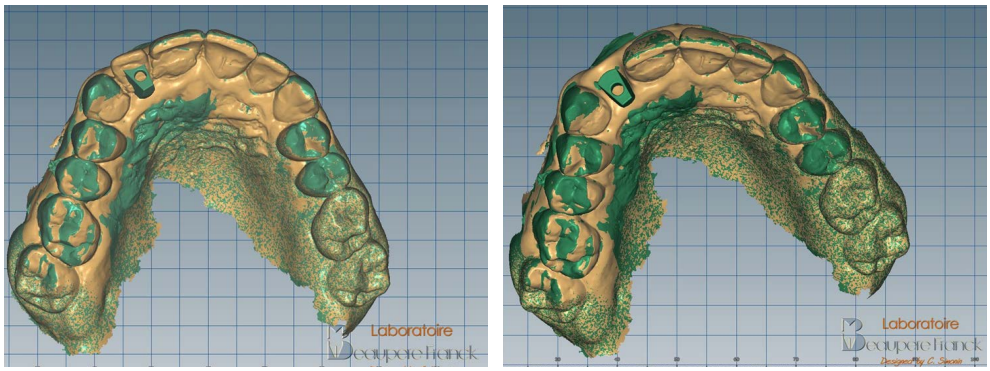

The patient's initial situation shown on left, and current situation shown on the right

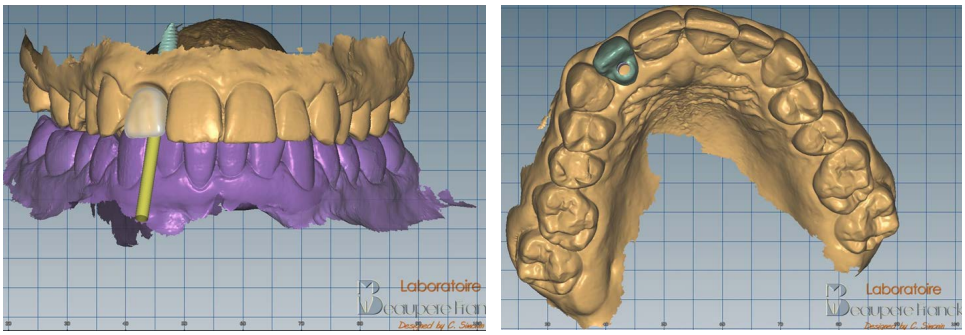

Restorative design in Exocad software

The crown with its Ti-base abutment, which was selected from the prosthetic pillars library of the MIS V3 implant system, we designed in the CAD software. The temporary crown was manufactured with a short pillar of 0.5mm and was adjusted prior to placement.

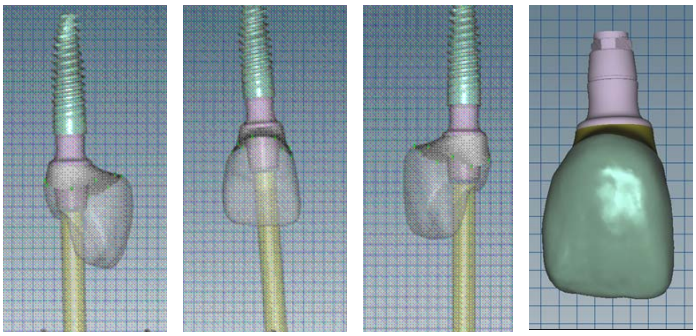

CAD design of the crown

Screw-retained crown

The temporary crown was placed, and a control radiograph was taken to confirm the placement and installation. Intraoral photos were taken showing the final adjusted temporary crown.

Final adjusted temporary crown

The patient was seen at both 1 week and 3 month post-operative intervals. A radiographic control image was taken at the 3 month post-operative appointment to verify success of placement and installation.

1 week post-operative follow-up

3 month post-operative follow up with radiograph to confirm result

Dr. Mithridade Davarpanah

Dr. Mithridade Davarpanah is a medical doctor, stomatologist, certified in periodontology, diplomat of the American Board of Periodontology and member of the French Academy of Surgery.

He was successively Associate Professor at the Southern California University of Los Angeles and Paris VI. Between 1995 and 1998, he is the scientific vice-president of the French Society of Periodontology. He is a member of several international societies, periodontology and implantology. He is Chief of Service of the Oral Rehabilitation Center of the American Hospital of Paris.

His private clinical practice in Paris is limited to oral surgery, periodontology and implantology. He has extensive experience with bone grafts.

He is the author of numerous articles published in national and international journals as well as several books on subjects as varied as halitosis, oral surgery and implantology. His Manual of Clinical Implantology, translated into a dozen languages, was very well received by colleagues wishing to learn this discipline. The second edition, completely revised and updated, was received in the same way. In addition, he recently published one of the first books on theory and practice of immediate loading, immediately translated into English.

He is a much appreciated speaker in Europe and the United States.